

The Humane Society Institute for Science and Policy  
**Animal Studies Repository**

6-2007

# Cetacean brains: How aquatic are they?

Lori Marino

Follow this and additional works at: <https://animalstudiesrepository.org/anatom>

 Part of the [Animal Structures Commons](#), [Animal Studies Commons](#), and the [Veterinary Anatomy Commons](#)

# Cetacean Brains: How Aquatic Are They?

LORI MARINO\*

Neuroscience and Behavioral Biology Program, Emory University, Atlanta, Georgia

---

---

## ABSTRACT

The adaptation of cetaceans to a fully aquatic lifestyle represents one of the most dramatic transformations in mammalian evolutionary history. Two of the most salient features of modern cetaceans are their fully aquatic lifestyle and their large brains. This review article will offer an overview of comparative neuroanatomical research on aquatic mammals, including analyses of odontocete cetacean, sirenian, pinniped, and fossil archaeocete brains. In particular, the question of whether a relationship exists between being fully aquatic and having a large brain is addressed. It has been hypothesized that the large, well-developed cetacean brain is a direct product of adaptation to a fully aquatic lifestyle. The current consensus is that the paleontological evidence on brain size evolution in cetaceans is not consistent with this hypothesis. Cetacean brain enlargement took place millions of years after adaptation to a fully aquatic existence. Neuroanatomical comparisons with sirenians and pinnipeds provide no evidence for the idea that the odontocete's large brain, high encephalization level, and extreme neocortical gyrification is an adaptation to a fully aquatic lifestyle. Although echolocation has been suggested as a reason for the high encephalization level in odontocetes, it should be noted that not all aquatic mammals echolocate and echolocating terrestrial mammals (e.g., bats) are not particularly highly encephalized. Echolocation is not a requirement of a fully aquatic lifestyle and, thus, cannot be considered a sole effect of aquaticism on brain enlargement. These results indicate that the high encephalization level of odontocetes is likely related to their socially complex lifestyle patterns that transcend the influence of an aquatic environment. *Anat Rec*, 290:694–700, 2007.

© 2007 Wiley-Liss, Inc.

**Key words: encephalization; cetacean; odontocetes; aquatic adaptation**

---

---

The modern mammalian order Cetacea consists of two modern suborders comprising 11 species of Mysticetes (large rorqual and baleen whales) and 67 species of Odontocetes (dolphins, porpoises, and toothed whales). The monophyletic order shared an ancestor with modern Artiodactyla (even-toed ungulates) over 60 million years ago (Thewissen et al., 2001) and diverged from its terrestrial counterpart approximately 52 million years ago (Gingerich and Uhen, 1998), when fossil evidence indicates a transition to a semiaquatic lifestyle. By no more recently than 40 million years ago, these early cetaceans (called archaeocetes) were fully aquatic (Uhen, 1998). By the beginning of the Oligocene epoch (approximately 33–34 million years ago) the archaeocete suborder, for all intents and purposes, was extinct and had been replaced

by the two modern suborders Mysticeti and Odontoceti (Barnes, 1985), collectively known as Neoceti.

The adaptation of cetaceans to a fully aquatic lifestyle represents one of the most dramatic transformations in mammalian evolutionary history (see review in Uhen,

---

Grant sponsor: The National Science Foundation.

\*Correspondence to: Lori Marino, Neuroscience and Behavioral Biology Program, 1462 Clifton Road, Suite 304, Emory University, Atlanta, GA 30322. E-mail: lmarino@emory.edu

DOI 10.1002/ar.20530

Published online in Wiley InterScience (www.interscience.wiley.com).

2007, this issue). Significant modifications occurred at all levels of physiology and morphology, including changes in the nervous system (e.g., underwater vision: Mass and Supin, 2007, this issue; underwater hearing: Nummela et al., 2007, this issue; Parks et al., 2007, this issue). Some of these features, such as the loss of hindlimbs, are obviously direct adaptations to the unique challenges of the aquatic environment. Others, such as increased brain size, are not so easily recognized as an aquatic adaptation. Nevertheless, two of the most salient features of modern cetaceans are their fully aquatic lifestyle and their large brains, which remains the focus of strong interest in the scientific community and the general public. This study will review the paleontological and neuroanatomical data in an attempt to address the question of whether being fully aquatic and having a large brain are related.

### LARGE BRAINS AND HIGH ENCEPHALIZATION LEVELS

Modern cetacean brains are among the largest of all mammals in both absolute mass and in relation to body size. The largest brain on earth today belongs to the sperm whale (*Physeter macrocephalus*) with an average adult brain size of 8,000 g (Marino, 2002). More specifically, brain size is often expressed as an encephalization quotient, or EQ (Jerison, 1973), which is a value that represents how large or small the brain of a given species is compared with other species of the same average body weight. The EQ for modern humans is 7.0. Our brains are seven times the size one would expect for a species with our body size. Almost all odontocetes possess above-average encephalization levels compared with other mammals. Numerous odontocete species possess EQs in the range of 4 to 5, that is, they possess brains four to five times larger than one would expect for their body weights. Many of these odontocete values are second only to those of modern humans and significantly higher than any of the nonhuman anthropoid primates (highest EQ ~ 3.3) (Marino, 1998).

EQs of mysticetes are all below 1 (Marino, 2002) because of an uncoupling of brain size and body size in very large (and especially aquatic) animals. However, the large absolute sizes, high degrees of cortical convolution, and highly derived morphology establish that mysticete brains have, in addition to odontocete brains, undergone substantial enlargement and elaboration during the course of their evolution (Oelschlager and Oelschlager, 2002). Most of the features of odontocete brain anatomy are shared with mysticetes. However, given that mysticete EQ values are biased for the aforementioned reason and relatively little is known about mysticete brains compared with odontocete brains, the remainder of this study will focus exclusively on odontocetes. Table 1 displays, by family, average brain weight, average body weight, and EQ (based on the formula derived by Jerison, 1973) for 26 species of extant odontocetes with sexes combined. There were no significant differences in EQ between sexes.

In summary, odontocete brains are among the largest modern mammalian brains and, in general, odontocetes are the most highly encephalized mammalian suborder next to our own species. There are two main domains of evidence that can be brought to bear on the question of

whether these outstanding features of odontocete brains are evolutionarily connected with a fully aquatic existence. These domains are (1) the paleontological data on how odontocete brain size changed over time and (2) the neuroanatomical data on which brain structures contributed the most to the enlarged brain mass of odontocetes, and the comparative data on other aquatic mammals.

### PALEONTOLOGICAL EVIDENCE

All members of the early suborder Archaeoceti possessed relatively small brains and low encephalization levels. The average encephalization level for archaeocetes was 0.5 (using Jerison's formula) (Marino et al., 2004a). Computer tomography-based analyses of fossil odontocete cranial and postcranial material showed that there were two significant increases in encephalization level in the past 47 million years among cetaceans (Marino et al., 2004a). The relevant question is whether these patterns of increase are associated with the pattern of adaptation to a fully aquatic environment in a way that suggests there is a connection between the two. The most recent increase in encephalization occurred by 15 million years ago and was limited to the superfamily Delphinoidea. Most importantly, the first and largest magnitude increase in encephalization occurred approximately 35 million years ago at the Eocene–Oligocene transition and coincided with the demise of the Archaeoceti and the emergence of the Neoceti (again, early forms of modern dolphins and whales which, at the beginning, included both the first odontocetes and mysticetes). Figure 1 displays the mean EQ levels for archaeocetes and odontocetes over 47 million years up to the present. Shown is an indicator of the time of the first major increase in encephalization and the period bounded by the first fully aquatic archaeocetes and the last archaeocetes. A comparison of the time of this major increase to the period of adaptation to a fully aquatic environment shows that archaeocetes were fully aquatic for at least 8–10 million years before the major increase in encephalization (Marino et al., 2004a). Throughout the entire period that archaeocetes were becoming fully aquatic, and for approximately 10 million years after the achievement of a fully aquatic lifestyle, there was no change in encephalization level. The increase in encephalization occurred only with the emergence of Neoceti. This pattern of evidence does not support the idea that adaptation to a fully aquatic environment drove an increase in encephalization levels in cetaceans. The increase in encephalization was apparently connected to the new characteristics of the Neoceti.

### NEUROANATOMICAL EVIDENCE

The paleontological evidence shows that the events that led to a fully aquatic existence and increased encephalization in cetaceans are not temporally correlated in any way that would suggest a functional connection between the two. Instead, the major increase in cetacean encephalization did not occur until the emergence of the Neoceti, who were all fully aquatic. The very earliest Neoceti manifested significantly larger encephalization levels than the very latest archaeocetes. But the brains of early neocetes did not simply enlarge

**TABLE 1. Cetacean brain weight, body weight, and encephalization quotient (EQ)**

Species common name (taxonomic name) by Family	Brain wt (g)	Body wt (g)	EQ
<b>Delphinidae</b>			
Bottlenose dolphin ( <i>Tursiops truncatus</i> )	1,824	209,530	4.14
Common dolphin ( <i>Delphinus delphis</i> )	815	60,170	4.26
Risso's dolphin ( <i>Grampus griseus</i> )	2,387	328,000	4.01
Pacific white-sided dolphin ( <i>Lagenorhynchus obliquidens</i> )	1,148	91,050	4.55
Atlantic white-sided dolphin ( <i>Lagenorhynchus acutus</i> )	1,103	244,667	2.25
Long-finned pilot whale ( <i>Globicephala melas</i> )	2,893	943,200	2.39
Killer whale ( <i>Orcinus orca</i> )	5,059	1,955,450	2.57
False killer whale ( <i>Pseudorca crassidens</i> )	2,534	350,098	4.03
Spinner dolphin ( <i>Stenella longirostris</i> )	660	66,200	3.24
Striped dolphin ( <i>Stenella coeruleoalba</i> )	940	261,099	2.94
Rough-toothed dolphin ( <i>Steno bredanensis</i> )	1,542	124,857	4.95
Tucuxi dolphin ( <i>Sotalia fluviatilis</i> )	688	42,240	4.56
<b>Phocoenidae</b>			
Harbor porpoise ( <i>Phocoena phocoena</i> )	540	51,193	2.95
Dall's porpoise ( <i>Phocoenoides dalli</i> )	866	86,830	3.54
<b>Platanistidae</b>			
Ganges river dolphin ( <i>Platanista gangetica</i> )	295	59,630	1.55
<b>Iniidae</b>			
Chinese river dolphin ( <i>Lipotes vexillifer</i> )	510	82,000	2.17
Amazon river dolphin ( <i>Inia geoffrensis</i> )	634	92,004	2.51
Franciscana ( <i>Pontoporia blainvillei</i> )	221	34,859	1.67
<b>Physeteriidae</b>			
Pygmy sperm whale ( <i>Kogia breviceps</i> )	1,012	305,000	1.78
Dwarf sperm whale ( <i>Kogia simus</i> )	622	168,500	1.63
Sperm whale ( <i>Physeter macrocephalus</i> )	8,028	35,833,330	0.58
<b>Ziphiidae</b>			
Cuvier's beaked whale ( <i>Ziphius cavirostris</i> )	2,004	2,273,000	0.92
Gervais' beaked whale ( <i>Mesoplodon europaeus</i> )	2,149	1,465,000	2.11
Blainville's beaked whale ( <i>Mesoplodon densirostris</i> )	1,425	770,500	1.39
<b>Monodontidae</b>			
Beluga whale ( <i>Delphinapterus leucas</i> )	2,083	636,000	2.24
Narwhal ( <i>Monodon monoceros</i> )	2,997	1,578,330	1.76

uniformly. Various structures underwent modifications in relative size and morphology over time. Therefore, by examining various key structures of modern odontocete brains, we can obtain clues as to what factors drove the increase in encephalization in odontocetes. Likewise, we can determine whether the aquatic environment, if not directly, then indirectly, played a role in odontocete encephalization.

In the analysis of brain evolution, a simple and self-evident principle forms the basis for the relationship between neuroanatomy and function. This is the Principle of Proper Mass (Jerison, 1973), which states that the mass of neural tissue controlling a particular function is correlated with the amount of information processing involved in that function. It also means that, across species, differences in the relative masses of neural structures represent differences in the relative importance of those functions. Therefore, we can ask what parts of the modern odontocete brain are enlarged (and likewise, what parts are reduced). This morphometric approach may yield clues as to which environmental and behavioral ecological factors were important in shaping the odontocete brain over time and, specifically, whether any

components of the high encephalization of odontocetes are necessarily driven by an aquatic lifestyle.

Furthermore, we can compare the odontocete brain with those of other aquatic mammals to determine whether there is any commonality that would, again, point to any necessary link between aquaticism and a high encephalization level. Therefore, in this section, odontocete brain structures that have undergone substantial change (mostly enlargement) will be compared with those in both the fully aquatic Sirenia (manatees and dugongs) and the semiaquatic Pinnipedia (sea lions, walruses, and seals). Sirenia are fully aquatic, as are odontocetes, but, as slow-paced herbivores, do not share the fast-paced carnivorous feeding ecology of odontocetes. Pinnipeds have a behavioral ecology that is more similar to odontocetes (piscivory), but are not fully aquatic and spend a varying, but not insignificant, percentage of their time on land. Therefore, none of these comparisons are ideal. However, comparisons of outstanding brain features in odontocetes with these other two aquatic groups can provide clues as to whether these features were driven by an aquatic existence or whether they were shaped by other factors specific only to odontocetes.

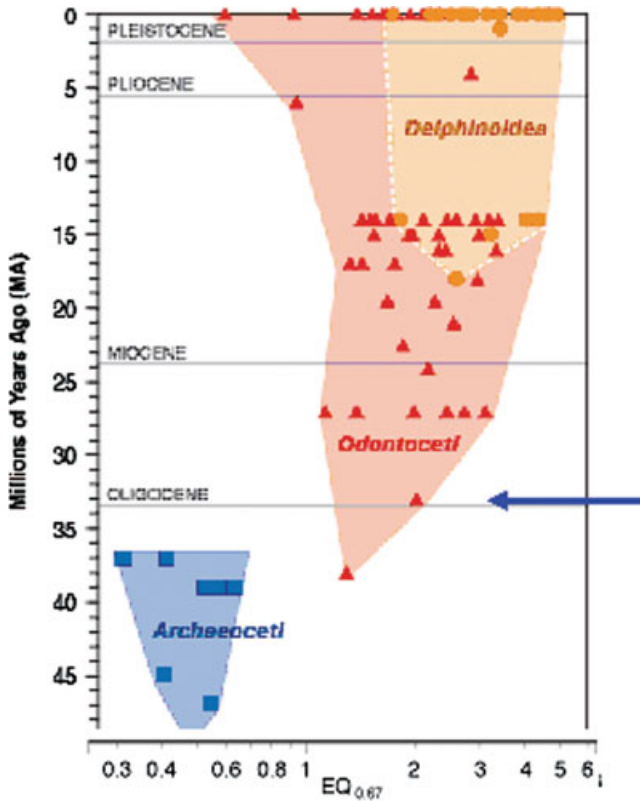


Fig. 1. Mean encephalization quotient (EQ) levels for archaeocetes and odontocetes over 47 million years up to the present. Earliest and most recent archaeocetes in the database are bounded in blue. The blue arrow indicates the first significant increase in EQ occurs with earliest emergence of Neocetes.

**EQ, Telencephalic Surface Area, and Configuration**

**Odontocetes.** As discussed, odontocetes possess the highest encephalization levels of all nonhuman mammals. The EQs of most modern odontocetes are generally on a par with modern primates but many species possess much higher EQs of 4.0–5.0, values that are second only to modern humans. The odontocete telencephalon, which is arranged into three concentric tiers of cortical tissue, accounts for much of the total brain volume (e.g., 63% in the franciscana, *Pontoporia blainvillei*, and 87% in the sperm whale, *Physeter macrocephalus*). Although odontocete neocortex is relatively thin, with a maximum width of 1.8 mm (Ridgway and Brownson, 1984), it is regionally highly differentiated and cytoarchitecturally complex (Hof et al., 2005; Oelschlagner and Oelschlagner, 2002). In addition to the size of the brain and its structures, the cetacean telencephalon is among the most highly convoluted of all mammals. One way to express the evolutionary elaboration of neocortical volume is by measuring surface area in relation to total brain size. Surface area indicates the degree of neocortical volumization that has occurred over time and is positively correlated with degree of convolution or gyrification. Human neocortical surface area is approximately 2,275 cm<sup>2</sup> and average total brain weight is 1,300 g. Therefore,

the gyrification index for modern humans is approximately 1.75. In the bottlenose dolphin (*Tursiops truncatus*) and common dolphin (*Delphinus delphis*), neocortical surface areas have been measured as 3,745 cm<sup>2</sup> and 2,136 cm<sup>2</sup> and average total brain weights as 1,587 g and 802 g, respectively (Ridgway and Brownson, 1984). Therefore, the gyrification indices for these two odontocete species, 2.4 and 2.7, respectively, substantially exceed that of modern humans. Furthermore, a qualitative description of the killer whale (*Orcinus orca*) brain suggests a neocortical gyrification index even higher than in *Tursiops* and *Delphinus* (Marino et al., 2004b).

In addition to their large highly convoluted telencephalon, electrophysiological mapping studies show that odontocetes exhibit a highly unusual topography of sensory–motor zones. Primary visual cortex is located on the vertex of the hemisphere in the lateral gyrus instead of the typical caudal location in the occipital lobe. The primary auditory cortex lies in a belt-like area immediately adjacent to the visual cortex in the suprasylvian gyrus. Secondary auditory cortex lies lateral to the primary auditory field in the medial ectosylvian gyrus (Ladygina et al., 1978; Supin et al., 1978). The cortical adjacency of the visual and auditory primary cortices in odontocetes is highly unusual in mammals with large brains. The motor and somatosensory cortices are rostral to the visual and auditory regions. Therefore, all of the projection zones of the cetacean brain are confined to one region of the telencephalic surface leaving a vast expanse of remaining nonprojection cortical tissue lateral and posterior to those zones. This nonprojection tissue may be considered “higher-order integrative” or “associative” to distinguish it from the primary and secondary projection zones. Finally, it is important to bear in mind that, with the exception of the nearly blind river dolphins, hyperproliferation of auditory functions did not occur at the expense of visual functions (Ridgway, 1990). In summary, the highly unusual odontocete neocortex is greatly expanded and features an extensive field apparently involved in “higher order-integrative” function.

**Sirenians and Pinnipeds.** On the other end of the spectrum from odontocete brains, sirenian brain size and gyrification has been markedly conservative. The EQ of the Florida manatee (*Trichechus manatus*) is approximately 0.35 and the dugong (*Dugong dugon*) approximately 0.5 (O’Shea and Reep, 1990). Both of these values are well below average. The sirenian telencephalon averages a high 71–73% of total brain volume and the neocortex is well differentiated, but the overall volume of the brain in relation to the body is much lower than in odontocetes. In terms of level of convolution, the sirenian brain is essentially a polar opposite to the odontocete brain. The sirenian telencephalon is almost lissencephalic (lacking gyri and sulci) and cortical thickness, averaging approximately 4 mm, is extreme. It has been suggested that sirenian cortical thickness is due to high white matter volume, which has also restrained gray matter gyrification (Reep and O’Shea, 1990). Although no electrophysiological mapping studies have been done on sirenians, there has been speculation about the functional roles played by various cortical areas based on cytoarchitectural data. These



observations suggest that sirenian cortical fields are more similar to those in other mammals than in cetaceans (Marshall and Reep, 1995).

Modern pinnipeds possess EQs that are average to above average, but none possess EQs in the highest ranges of odontocete levels. For instance, the ringed seal (*Pusa hispida*) possesses an EQ of 1.75, the harbor seal (*Phoca vitulina*) 2.08, and the Weddell seal (*Leptonychotes weddellii*) 0.76 (Marino, 2002). The pinniped cerebral cortex is more convoluted than that of many terrestrial mammals but, again, does not appear to reach the same level of proliferation in surface area exhibited by most odontocetes. The general appearance of the neocortex and its surface configuration in pinnipeds corresponds fairly well to that of their terrestrial relatives, the carnivores (Oelschläger and Oelschläger, 2002).

The highly expanded neocortical volume and unusual sensory-motor surface configuration in odontocetes is not shared with noncetacean aquatic mammals. But do these features of odontocete brains bear any relation to the kind of fully aquatic fast-paced lifestyle led by odontocetes? Neocortical tissue is the substrate for sensory integration and high-level cognitive processing. The vast field of integrative neocortex in the odontocete brain suggests that it evolved to handle several domains of information processing, that is, general intelligence. Although one driver for the large odontocete neocortex may be the fast-paced carnivorous feeding strategy, there is nothing about this lifestyle that is specific to the aquatic environment. In fact, carnivory and other complex feeding strategies are positively correlated with increased brain and neocortical size in many terrestrial groups (see Marino, 2005, for a review). Also, the unusual surface configuration of the odontocete telencephalon is not shared with any other aquatic order and, while it indicates that odontocete brains have been on a different trajectory of expansion than other aquatic mammals, there is nothing about the particular arrangement that is directly related to aquaticism. Adjacency of visual and auditory zones might be said to be related to echolocation. There is experimental behavioral evidence to suggest that dolphins are highly proficient at cross-modal information processing (Pack and Herman, 1995), but echolocation alone is not a requirement of an aquatic existence (e.g., bats also echolocate).

### Reduction of Olfaction and Reproportioning of the Limbic System

**Odontocetes.** Another key feature of odontocete brain evolution is the complete loss of olfactory structures in adults; fetuses possess small olfactory structures (Buhl and Oelschläger, 1988; Marino et al., 2001) that regress completely shortly after birth. Adult mysticetes possess a reduced olfactory system (Oelschläger and Oelschläger, 2002). What is particularly interesting about the loss of olfaction in odontocetes is that it appears to be correlated with another important modification of odontocete brains, that is, the re-proportioning of the limbic system. The limbic system is a complex set of structures that lies ventrolateral to the thalamus. The system is highly involved in emotional processing and memory formation. The loss of olfactory input in odontocetes has resulted in a substantial reduction in the hippocampus (archicortex), fornix, and mammillary bodies

(Jacobs et al., 1979; Morgane et al., 1980) in odontocetes. On the other hand, the amygdala is large and well-developed in odontocetes and other cetaceans (Schwerdtfeger et al., 1984), reflecting the maintenance of substantial nonolfactory sources of input to this structure. The reduction of the hippocampus and related structures in odontocetes is particularly striking in light of the fact that odontocetes possess robust memory and learning skills (Mercado et al., 1998, 1999) which, in other mammals, depend highly on the hippocampus. An interesting possibility is that some learning and memory functions were transferred from the reduced hippocampal formation to the extremely well-developed cortical limbic lobe (periarchicortical field above the corpus callosum and the entorhinal cortex) in odontocetes (Oelschläger and Oelschläger, 2002; Marino et al., 2003, 2004b). This hypothesis would account for the copious behavioral evidence for strong learning and memory skills in odontocetes (Herman, 2006).

**Sirenians and Pinnipeds.** What aspects, if any, of loss of the olfactory system and concomitant hippocampal reduction in odontocetes is shared with sirenians and pinnipeds? In all aquatic mammals, olfactory systems are reduced. In sirenians, the olfactory system is rudimentary and, similarly to odontocetes, they lack a vomeronasal organ (Mackay-Sim et al., 1985). In pinnipeds, presumably because they are semiaquatic, olfactory structures are small compared with terrestrial carnivores, but substantially well developed compared with sirenians and odontocetes. Pinnipeds also possess a vomeronasal organ (Oelschläger and Oelschläger, 2002). These observations support the hypothesis that, in mammals, secondary adaptation to an aquatic environment leads to the reduction of the olfactory senses. However, only odontocetes have lost olfaction altogether. As in odontocetes, the sirenian hippocampus is reduced (Oelschläger and Oelschläger, 2002), but sirenians do not possess the extensively developed limbic lobe (periarchicortex and entorhinal cortex) as odontocetes do. Therefore, in sirenians, although there is a similar reduction of olfactory and hippocampal structures, their brain does not seem to have compensated (if indeed that is what the odontocete brain has done) with an elaborate periarchicortical and entorhinal cortex. In pinnipeds, the hippocampus is large and well-developed and not different from that of terrestrial mammals. Therefore, although an aquatic lifestyle is correlated with olfactory reduction, only odontocetes (and to a lesser extent sirenians) have taken this reduction to an extreme while, at the same time, developing the limbic lobe as a possible alternative to a reduced hippocampus. The functional hypothesis that the extensive limbic lobe of odontocetes is a direct response to reduced hippocampal function has yet to be fully tested. Nevertheless, the anatomical reality exists that odontocetes are the only aquatic mammals that possess a unique combination of a small hippocampus and a large limbic lobe.

### Auditory System

**Odontocetes.** Auditory structures in odontocete brains are greatly enlarged (Ridgway, 2000). The vestibulocochlear nerve is immense in diameter and is composed of relatively more auditory than vestibular fibers

(Oelschlaeger and Oelschlaeger, 2002). The ventral cochlear nucleus, trapezoid bodies, lateral lemniscus, and inferior colliculi (auditory tectum) are all greatly enlarged in comparison with terrestrial mammals. In odontocetes, the inferior colliculus can be at least four times the size of the superior colliculus (Marino et al., 2003). The auditory tectum projects to a large medial geniculate nucleus in the massive thalamus. Therefore, the midbrain of odontocetes is massive partly because of enlarged auditory structures. Likewise, the primary and secondary auditory projection zones on the cerebral surface are extensive (Ladygina et al., 1978; Supin et al., 1978).

**Sirenians and Pinnipeds.** Pinnipeds possess well-developed auditory structures. The sirenian auditory system is only moderately developed (although the inferior colliculus is larger than the superior colliculus). Neither pinniped nor sirenian auditory systems reach the level of development found in odontocetes (Oelschlaeger and Oelschlaeger, 2002).

Odontocetes, the only aquatic mammals with echolocation, possess the most highly developed and enlarged auditory brain structures. It might be tempting, therefore, to base an explanation for the high encephalization level of odontocetes on the expansion of auditory regions. However, despite the large subcortical and cortical auditory processing regions in the odontocete brain, most of the odontocete neocortex is not auditory per se. Therefore, the massiveness of the telencephalon cannot be attributed solely or even mainly to audition. As discussed before, odontocetes possess a large expanse of "integrative neocortex," which is consistent with the experimental literature showing highly sophisticated general cognitive processing capacities (Herman, 2002, 2006). If acoustic processing is playing a role in odontocete brain expansion, it is clearly doing so at a very high level of cognitive integration.

## CONCLUSIONS AND DISCUSSION

The most notable feature of cetacean brains is the highly developed telencephalon and substantially higher encephalization level than found in all other nonhuman mammals. In this study, two lines of evidence are examined for the hypothesis that the large, well-developed cetacean brain is a direct product of adaptation to a fully aquatic lifestyle. The paleontological data are not consistent with this notion. It shows that brain enlargement in cetaceans took place millions of years after the period of adaptation to a fully aquatic existence had ended. Comparisons of volumetric proportions of various structures across modern odontocetes, sirenians, and pinnipeds also do not provide strong evidence for this hypothesis. No other aquatic mammals share the same constellation of neuroanatomical structures or the generally high encephalization level of cetaceans.

The highly expanded neocortical volume and unusual sensory-motor surface configuration in odontocetes is not shared with other aquatic mammals. Furthermore, although olfactory structures and parts of the hippocampal formation were significantly reduced in all aquatic mammals, only odontocetes show a possible compensatory development in the form of a highly convoluted and massive limbic lobe. Finally, the enlarged auditory structures of odontocetes may be due to the use of echoloca-

tion. Echolocation per se is frequently overestimated as a reason for the high encephalization level in odontocetes. Not all aquatic mammals echolocate and echolocating terrestrial mammals, such as bats, are not particularly highly encephalized. Therefore, although echolocation clearly evolved to work in an aquatic environment in odontocetes, it is not a requirement of a fully aquatic lifestyle and cannot be considered a *direct* effect of aquaticism on brain enlargement. The voluminous neocortical region, and particularly the expansive higher-level integrative neocortical field in the odontocete brain, are more a function of their general cognitive complexity. The neuroanatomical evidence suggests that the large cetacean brain supports a complex general intelligence, perhaps driven by factors convergent with other socially complex mammals. These results indicate that the high encephalization level of odontocetes is a function of lifestyle patterns, such as being socially complex and highly communicative predators that transcend the aquatic-terrestrial dimension.

## LITERATURE CITED

- Barnes LG. 1985. Review: general features of the paleobiological evolution of Cetacea. *Mar Mammal Sci* 1:90-93.
- Buhl EH, Oelschlaeger HA. 1988. Morphogenesis of the brain in the harbour porpoise. *J Comp Neurol* 277:109-125.
- Gingerich PD, Uhen MD. 1998. Likelihood estimation of the time of origin of cetacean and the time of divergence of cetacean and Artiodactyla. *Paleo-electronica* 2:1-47.
- Herman LM. 2002. Exploring the cognitive world of the bottlenosed dolphin. In: Bekoff M, Allen C, Burghardt GM., editors. *The cognitive animal: empirical and theoretical perspectives on animal cognition*. Cambridge: MIT Press. p 275-283.
- Herman LH. 2006. Intelligence and rational behaviour in the bottlenosed dolphin. In: Hurley S, Nudds M, editors. *Rational animals?* Oxford: Oxford University Press. p 439-468.
- Hof P, Chanis R, Marino L. 2005. Cortical complexity in cetacean brains. *Anat Rec* 287A:1142-1152.
- Jacobs MS, McFarland WL, Morgane PJ. 1979. The anatomy of the brain of the bottlenose dolphin (*Tursiops truncatus*). Rhinencephalon (rhinencephalon): the archicortex. *Brain Res Bull* 4:1-108.
- Jerison HJ. 1973. *Evolution of the brain and intelligence*. New York: Academic Press.
- Ladygina TF, Mass AM, Supin AI. 1978. Multiple sensory projections in the dolphin cerebral cortex. *Zh Vyssh Nerv Deiat Im I P Pavlova* 28:1047-1054.
- Mackay-Sim A, Duvall D, Graves BM. 1985. The West Indian manatee (*Trichechus manatus*) lacks a vomeronasal organ. *Brain Behav Evol* 27:186-194.
- Marino L. 1998. A comparison of encephalization between odontocete cetaceans and anthropoid primates. *Brain Behav Evol* 51:230-238.
- Marino L. 2002. Brain size evolution. In: Perrin FA, Wursig B, Theissen H, editors. *Encyclopedia of marine mammals*. San Diego: Academic Press. p 158-162.
- Marino L. 2005. Big brains matter in novel environments. *Proc Natl Acad Sci U S A* 102:5306-5307.
- Marino L, Murphy TL, Gozal L, Johnson JI. 2001. Magnetic resonance imaging and three-dimensional reconstructions of the brain of the fetal common dolphin, *Delphinus delphis*. *Anat Embryol (Berl)* 203:393-402.
- Marino L, Pabst DA, McLellan WA, Sudheimer K, Johnson JI. 2003. Magnetic resonance images of the brain of a dwarf sperm whale (*Kogia simus*). *J Anat* 204:57-76.
- Marino L, McShea D, Uhen MD. 2004a. The origin and evolution of large brains in toothed whales. *Anat Rec* 281A:1247-1255.
- Marino L, Sherwood CC, Tang CY, Delman BN, Naidich TP, Johnson JI, Hof PR. 2004b. Neuroanatomy of the killer whale (*Orcinus*

- orca*) from magnetic resonance imaging. *Anat Rec* 281A:1256–1263.
- Marshall CD, Reep RL. 1995. Manatee cerebral cortex: cytoarchitecture of the caudal region in *Trichechus manatus latirostris*. *Brain Behav Evol* 45:1–18.
- Mass AM, Supin AY. 2007. Adaptive features of the aquatic mammals' eye. *Anat Rec* (this issue).
- Mercado E III, Murray SO, Uyeyama RK, Pack AA, Herman LM. 1998. Memory for recent actions in the bottlenosed dolphin (*Tursiops truncatus*): repletion of arbitrary behaviors using an abstract rule. *Anim Learn Behav* 26:210–218.
- Mercado E III, Uyeyama RK, Pack AA, Herman LM. 1999. Memory for action events in the bottlenosed dolphin. *Anim Cogn* 2: 17–25.
- Morgane PJ, Jacobs MS, McFarland WL. 1980. The anatomy of the brain of the bottlenose dolphin (*Tursiops truncatus*). Surface configurations of the telencephalon of the bottlenose dolphin with comparative anatomical observations in four other cetacean species. *Brain Res Bull* 5:1–107.
- Nummela S, Thewissen JGM, Bajpai S, Hussain ST, Kumar K. 2007. Sound transmission in archaic and modern whales: anatomical adaptations for underwater hearing. *Anat Rec* (this issue).
- Oelschläger HA, Oelschläger JS. 2002. Brains. In: Perrin FA, Wursig B, Thewissen H, editors. *Encyclopedia of marine mammals*. San Diego: Academic Press. p 133–158.
- O'Shea TJ, Reep RL. 1990. Encephalization quotients and life-history traits in the sirenian. *J Mammal* 71:534–543.
- Pack AA, Herman LM. 1995. Sensory integration in the bottlenosed dolphin: immediate recognition of complex shapes across the senses of echolocation and vision. *J Acoust Soc Am* 98:722–723.
- Parks SE, Ketten DR, O'Malley JT, Arruda J. 2007. Anatomical predictions of hearing in the North Atlantic right whale. *Anat Rec* (this issue).
- Reep RL, O'Shea TJ. 1990. Regional brain morphometry and lissencephaly in the Sirenian. *Brain Behav Evol* 35:185–194.
- Ridgway SH. 1990. The central nervous system of the bottlenose dolphin. In: Leatherwood S, Reeves RR, editors. *The bottlenose dolphin*. San Diego: Academic Press. p 69–100.
- Ridgway SH. 2000. The auditory central nervous system of dolphins. In: Au W, Popper A, Fay R, editors. *Hearing in whales and dolphins*. NY: Springer Verlag. p 273–293.
- Ridgway SH, Brownson RH. 1984. Relative brain sizes and cortical surface areas in odontocetes. *Acta Zool Fenn* 172:149–152.
- Schwerdtfeger WK, Oelschläger HA, Stephan H. 1984. Quantitative neuroanatomy of the brain of the La Plata dolphin, *Pontoporia blainvillei*. *Anat Embryol (Berl)* 170:11–19.
- Supin AY, Mukhametov LM, Ladygina TF, Popov VV, Mass AM, Poliakova IG. 1978. Electrophysiological studies of the dolphin's brain. Moscow: Izdatel'ato Nauka.
- Thewissen JGM, Williams EM, Roe LJ, Hussain ST. 2001. Skeletons of terrestrial cetaceans and the relationship of whales to artiodactyls. *Nature* 413:277–281.
- Uhen MD. 1998. Middle to late eocene basilosaurines and dorudontines. In: Thewissen JGM, editor. *The emergence of whales*. New York: Plenum. p 29–61.
- Uhen MD. 2007. Evolution of marine mammals: back to the sea after 300 million years. *Anat Rec* (this issue).