

The Humane Society Institute for Science and Policy
Animal Studies Repository


2-2010

Hair Whorls in the Dog (*Canis familiaris*). I. Distribution

Lisa M. Tomkins
University of Sydney

Paul McGreevy
University of Sydney

Follow this and additional works at: <https://animalstudiesrepository.org/anatom>

 Part of the [Animal Structures Commons](#), [Animal Studies Commons](#), and the [Veterinary Anatomy Commons](#)

Recommended Citation

Tomkins, L. M., & McGreevy, P. D. (2010). Hair whorls in the dog (*Canis familiaris*). I. distribution. *The Anatomical Record: Advances in Integrative Anatomy and Evolutionary Biology*, 293(2), 338-350. <https://doi.org/10.1002/ar.21055>

This Article is brought to you for free and open access by the Humane Society Institute for Science and Policy. It has been accepted for inclusion by an authorized administrator of the Animal Studies Repository. For more information, please contact eyahner@humanesociety.org.



Hair Whorls in the Dog (*Canis familiaris*). I. Distribution

L.M. TOMKINS* AND P.D. MCGREEVY

Faculty of Veterinary Science, University of Sydney, New South Wales, Australia

ABSTRACT

Hair whorl characteristics were assessed in the domestic dog (*Canis familiaris*) in the regions of cephalic, cervical (dorsal, ventral, and lateral), thoracic and brachial axillary regions, the chest, shoulders, elbows, ventral abdominal region, and on the caudal thighs (ischiatric). They were classified as simple or tufted, and their position was recorded as the distance between their centers and bony landmarks within each region. The distribution of whorls was explored in a cohort of domestic dogs (N = 120) comprising a variety of breeds and cross-breeds, sourced from shelters (N = 60) and the general public (N = 60). Whorls observed in the majority of dogs in this cohort typically occurred on the chest, brachial axillary region, elbows, and ischiatic region. Atypical whorls were present in fewer than 20% of the population, and included those on the head (cephalic), cervical regions (dorsal, ventral, and lateral), shoulders, thoracic axillary region, and on the ventral abdominal region. The majority of whorls on dogs were classified as simple. In contrast, those located on the elbows and the majority of chest whorls were tufted. The presence and position of whorls were often associated with several variables including coat length and thickness, and the sex and source of the dog. The palpation and hair-cluster method of whorl assessment described in this article is best suited to dogs with short-to-medium coat lengths. The current methodology developed to assess hair whorl characteristics provides a framework for future investigations into any associations between hair whorl characteristics and other canine traits such as temperament. *Anat Rec*, 293:338–350, 2010. © 2010 Wiley-Liss, Inc.

Key words: hair whorl; hair coat; trichoglyphs; dog

Hair whorls are a manifestation of hair coat and have been studied in various species, including humans (Gworys and Domagala, 2003; Klar, 2003, 2005; Ziering and Krenitsky, 2003; Weber et al., 2006; Jansen et al., 2007); cattle (Grandin et al., 1995; Randle, 1998; Lanier et al., 2001; Meola et al., 2004; Evans et al., 2005); and horses (Murphy and Arkins, 2004; Górecka et al., 2006, 2007). The association between hair whorls and brain development reflects a common embryonic ectodermal origin shared by the integument and the nervous system (Smith and Gong, 1974). This association has been investigated mainly in humans, with non-human studies largely exploring relationships between whorl position and temperament. Non-human studies have almost exclusively focused on describing cephalic whorl characteristics, and have failed to report on whorls in other anatomical locations. There are few published data on hair

whorls in Canidae, and no known studies investigating canine whorl position, classification, and distribution. Therefore, the aim of the current study was to develop a methodology to assess the position and classification of whorls in the domestic dog. Assessment of a variety of

Grant sponsor: Australian Research Council; Grant number: LP0669908; Grant sponsors: NSW/ACT Guide Dogs and NSW Police Dog Unit.

*Correspondence to: L.M. Tomkins, 12 Brodie Street, Baulkham Hills, NSW 2153, Australia. Tel.: +61-402-123-863. Fax: +612-8002-4030. E-mail: tomkins@optushome.com.au

Received 20 May 2009; Accepted 22 September 2009

DOI 10.1002/ar.21055

Published online in Wiley InterScience (www.interscience.wiley.com).

TABLE 1. Breeds and their crosses used to assess hair whorl characteristics

Pure-bred	Number of Dogs	Mixed breeds	Number of Dogs
American Pit-bull Terrier (Red Nose)	5	American Staffordshire Terrier x	3
American Staffordshire Terrier	7	American Staffordshire Terrier x Bull Terrier	1
Australian Cattle Dog	3	American Staffordshire Terrier x Labrador	1
Beagle	4	American Staffordshire Terrier x Rottweiler	1
Border Terrier	1	Border Collie x Jack Russell Terrier	1
Boxer	2	Bullmastiff x American Staffordshire Terrier	1
Chihuahua	3	Chihuahua x Fox Terrier	2
Cocker Spaniel	1	Fox Terrier x	1
Dalmatian	7	German Shepherd x	1
English Cocker Spaniel	1	German Shepherd x Kelpie	3
Fox Hound	1	German Shepherd x Malamute	1
Fox Terrier (Miniature)	4	German Shepherd x Siberian Husky	1
German Shepherd	1	Greyhound x Golden Retriever	1
German Shorthaired Pointer	1	Jack Russell Terrier x	1
Golden Retriever	1	Jack Russell Terrier x Fox Terrier	1
Great Dane	1	Jack Russell Terrier x Kelpie	1
Grayhound	2	Kelpie x	1
Hungarian Vizsla	1	Kelpie x Australian Cattle Dog	1
Irish Water Spaniel	1	Kelpie x Border Collie	3
Irish Wolfhound	1	Kelpie x Rottweiler	2
Russell Terrier	5	Kelpie x Staffordshire Terrier	2
Kelpie	3	Labrador x	1
Labrador	4	Pug x	1
Maltese	4	Red Cattle Dog x	1
Poodle (Toy)	2	Rottweiler x Labrador	1
Rottweiler	1	Sharpei x Bullmastiff	1
Schnauzer (Miniature)	2	Shih-Tzu x Maltese	1
Shih-Tzu	1	Shih-Tzu x Poodle	1
Siberian Husky	1	Staffordshire Terrier x German Shepherd	1
Staffordshire Terrier	9	Terrier x Schnauzer	1
Whippet	1		

dog breeds was helpful in identifying breeds for which this novel methodology is suitable. Finally, whorl distribution in the current population is described.

MATERIALS AND METHODS

Animals

Source: One hundred twenty dogs were sourced from both a Sydney animal shelter [cadavers (shelter dogs); N = 60] and the University of Sydney Veterinary Teaching Hospital [live dogs (non-shelter dogs); N = 60]. All dogs available at both sites were sampled on days when the operator was visiting. The dogs were not subjected to selection by the operator.

Breeds: A variety of breeds and cross-breeds [as identified by the author (LT) or owners; see Table 1], representative of the general Australian domestic dog population were used to estimate whorl position and classification. The group comprised both female (N = 57; of which 20 were described by owners as having been spayed and 23 were unspecified) and male (N = 63; of which 18 were castrated).

Whorl Classification

Canine whorls in the current study were described as either simple or tufted. A simple whorl describes a focal point or center from which the hairs diverge in a flattened swirling pattern, whereas a tufted whorl describes

hairs converging from different directions to a central point, forming a tuft (Fig. 1).

Whorl Position

Whorl placement in this study was recorded in relation to where the center of the spiral lay. A pair of callipers was used to record the position of the whorl, in millimeters, in relation to bony landmarks within the region. A palpation and hair-cluster technique was used to identify the two focal points from which the distance would be measured; the center of the whorl and the palpable bony landmark. The center of a simple whorl could be determined visually, but palpation and manipulation of the hair-cluster was required to determine the center of a tufted whorl. In this technique, the point at which hair converged over the center of the whorl was located, and the tuft of hair was then held between the index finger and thumb to rotate the hair to expose the center of the tuft. To account for variation in size between different breeds and individual dogs, measurements were also taken to allow whorl distance to be expressed as a percentage distance from a skeletal feature, so position could be standardized and compared between breeds. For example, a standardization measurement for brachial axillary whorls was the distance from the cranial tip of the greater tubercle of the humerus to the most caudal point of the olecranon (SD). The position of the hair whorl was measured from the greater tubercle of the humerus (W). To express this measurement as a percentage

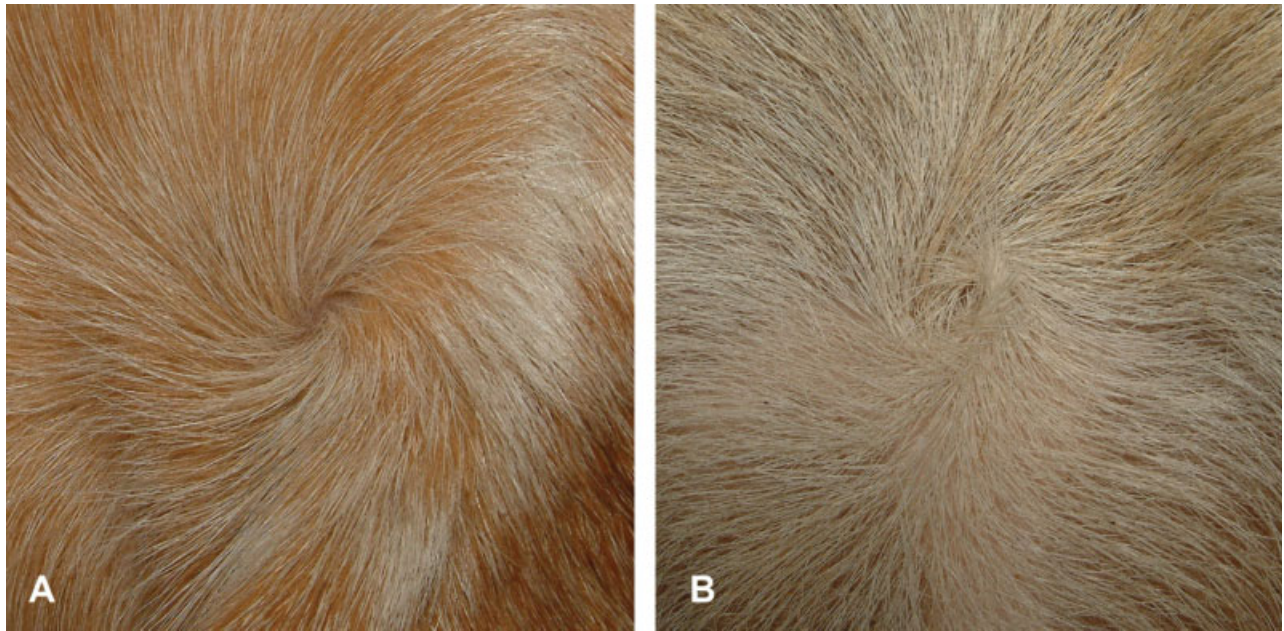

Fig. 1. Photographs of hair whorls demonstrating classification. **A:** A simple hair whorl. **B:** A tufted hair whorl.

distance, the formula $(W/SD) \times 100$ was used. However, there were four regions where such comparative standards were not available because the percentage distance could not be measured due to the absence of a suitable palpable bony landmark for standardization. For these positions, the raw measurement in millimeters is given. These positions include the distance of a whorl from the midline, first on the forearm, i.e., for both brachial axillary and shoulder measurements, and second from the tuber ischii in the ischiatic region. Last, the distance of an elbow whorl from the olecranon was also measured without a comparative standard.

Whorl positions were described as being to the left or right of the midline, corresponding to the animal's left or right side. To reduce the effect of mobile skin, positions of the dog and its appendages were consistent across subjects when assessing various regions. Dogs were assessed for cephalic, and dorsal and lateral cervical whorls, while positioned in lateral recumbency, with the nose held level with the dorsal border of the scapulae. Dogs were positioned in dorsal recumbency, with their necks extended level with the dorsum, to assess ventral mandibular, chest, and abdominal whorls. Axillary, shoulder, and elbow whorls were also assessed while the dog was in dorsal recumbency. When these whorls were characterized, the position of the thoracic limb was important, and as such, the humerus was held perpendicular to the radius and ulna, so that the elbow joint was at 90° flexion while the dog was assessed. Position of the dog differed between cadavers and live animals only when assessing ischiatic whorls. Live dogs were assessed while standing, with their pelvic limbs positioned so that the metatarsus was perpendicular to the ground. This pelvic leg angle was consistent when assessing ischiatic whorls in cadavers. In contrast, the cadavers were positioned in dorsal recumbency with both legs held to-

gether. To reduce variation as a result of post-mortem rigidity of the integument, cadavers were assessed 2–4 hr post-euthanasia, before the effects of rigor mortis set in. Whorl characteristics were measured by a single operator.

Cephalic whorls Whorls occur on the lateral surfaces of the face. Standard measurements were (i) distance between the tip of the nose and the occipital protuberance, and (ii) the widest distance between the zygomatic arches. Whorl position was measured as the lateral distance from the midline, and longitudinally from the occipital protuberance to a transverse line level with the whorl (Fig. 2). The side on which the whorl was situated was recorded as either the left or right of the midline. Position relative to the medial canthus of the eye was also recorded as rostral or caudal.

Cervical whorls

Dorsal whorls. Standard measurements for the assessment of dorsal whorls were (i) width of neck at the widest point, cranial to the scapulae at the C6/C7 level, and (ii) distance from the occipital protuberance to the point equidistant between the cranial angles of the scapulae (Fig. 3). Although no whorls in this location were observed, the intention was to measure the distance longitudinally from the occipital protuberance to a transverse line level with the whorl, and the distance laterally from the midline. The side of the neck on which the whorl would be situated would have also been recorded as to the left or right of the midline. To differentiate between a dorsal and lateral cervical whorl, if a whorl could be observed on the dorsal portion of the neck when viewed from above, then it would be considered a dorsal cervical whorl.

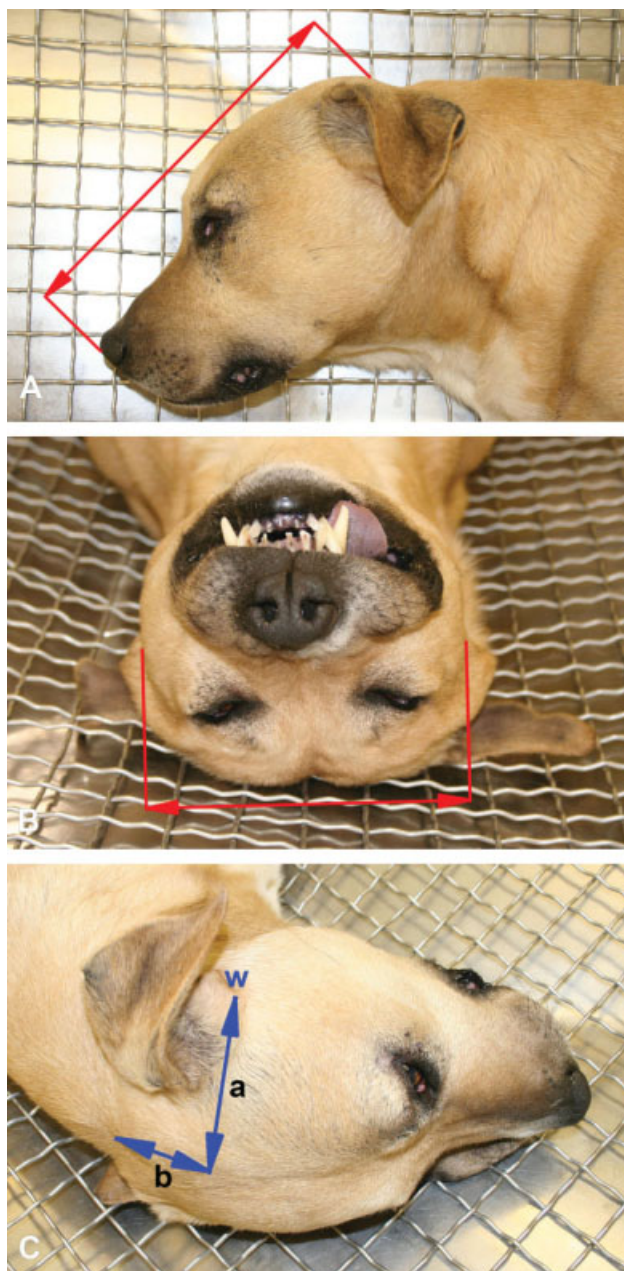


Fig. 2. Cephalic whorl measurements. **A**: Distance between the rostral tip of the nose and the occipital protuberance. **B**: Widest distance between the zygomatic arches. **C**: Measurement of a cephalic whorl (w); (a) laterally from the midline, and (b) longitudinally from the occipital protuberance to a transverse line at the level of the whorl.

Lateral whorls. Whorls may arise on one or both sides of the dog's neck. The depth of the neck equidistant between the angular process of the mandible and the cranial angle of the scapula was measured for standardization. Whorl position was measured as the distance from the ventral midline, and longitudinally from the occipital protuberance to a transverse line level with the whorl (Fig. 4).

Ventral mandibular whorls. After exposing the ventral surface of the head and neck by extending the neck,

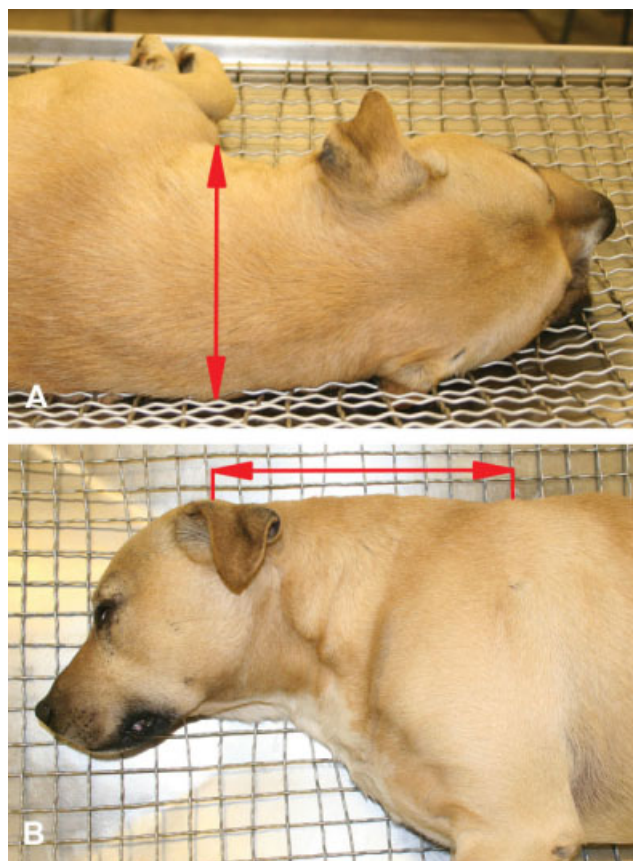


Fig. 3. Cervical dorsal whorl measurement. **A**: Measurement of the width of neck at the widest point. **B**: Distance from the occipital protuberance to the point equidistant between the cranial angles of the scapulae.

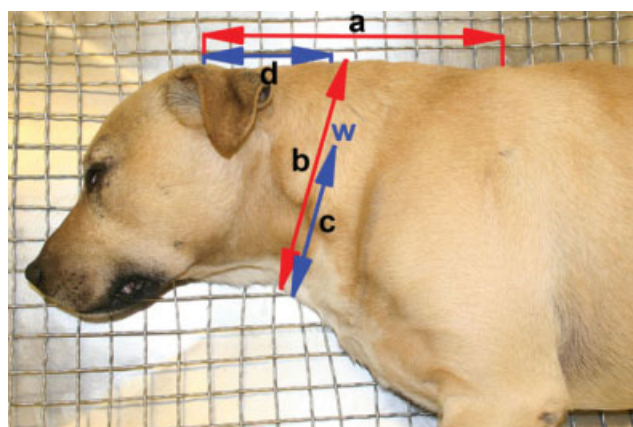


Fig. 4. Lateral whorl (w) measurement; (a) distance from the occipital protuberance to the point equidistant between the cranial angles of the scapulae; (b) depth of the neck equidistant between the angular process of the mandible and the cranial angle of the scapula; (c) distance from the whorl to the ventral midline; and (d) longitudinal distance from the whorl to the occipital protuberance.

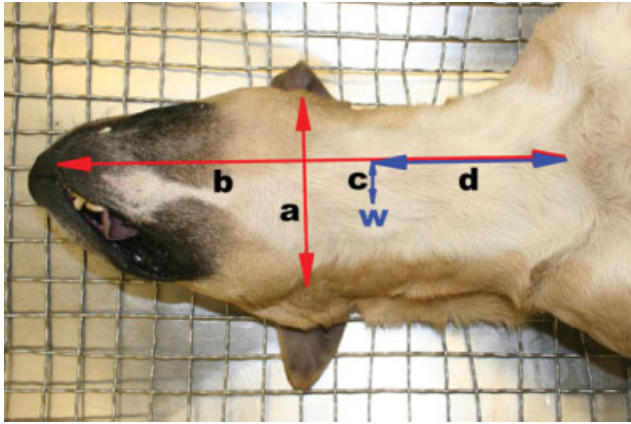


Fig. 5. Ventral mandibular whorl (w) measurement; (a) width between the angular process of the mandibles; (b) distance from the rostral tip of the lower lip to the cranial end of the manubrium of the sternum; (c) distance from whorl to ventral midline; and (d) distance from the whorl to the cranial end of the manubrium.

standard measurements were (i) width between the angular process of the mandibles and (ii) distance from the rostral tip of the lower lip to the cranial end of the manubrium of the sternum. Visual assessment was used to locate any whorl, and then, its distance from the ventral midline, and longitudinally from the cranial end of the manubrium to a transverse line level with the whorl was measured (Fig. 5). The whorl's position was classified as rostral or caudal to the angular process of the mandibles, and to the left or right of the midline.

Chest whorls. Chest whorls were assessed while the sternal region of the thoracic inlet was exposed. Standard measurements were (i) width between the acromion processes of the two scapulae, and (ii) distance from the cranial end of the manubrium to the caudal limit of the xiphoid process. Whorl position was measured as the longitudinal distance from a transverse line at the level of the manubrium, and laterally from the midline (Fig. 6). Position was also recorded as rostral or caudal to the manubrium, and left or right of the midline.

Axillary whorls. Axillary whorls can arise on both the medial surface of the thoracic limbs (brachial axillary whorls) and on the lateral surface of the thorax (thoracic axillary whorls). Dogs were, therefore, assessed for whorls in both positions.

Brachial axillary whorls. Whorls in the brachial region on the cranial aspect of the thoracic limbs were assessed. Distance from the cranial tip of the greater tubercle of the humerus to the most caudal point of the olecranon (point of the elbow) was measured for standardization. For both the left and right brachial axillary whorls, distance from the greater tubercle of the humerus, and the cranial midline of the brachium were measured (Fig. 7). Whorl placement was also recorded as medial or lateral to the brachial midline.

Thoracic axillary whorls. Standard measurements for thoracic axillary whorls were (i) width between the acromion processes of the two scapulae (Fig. 8), and (ii) distance from the cranial end of the manubrium to the

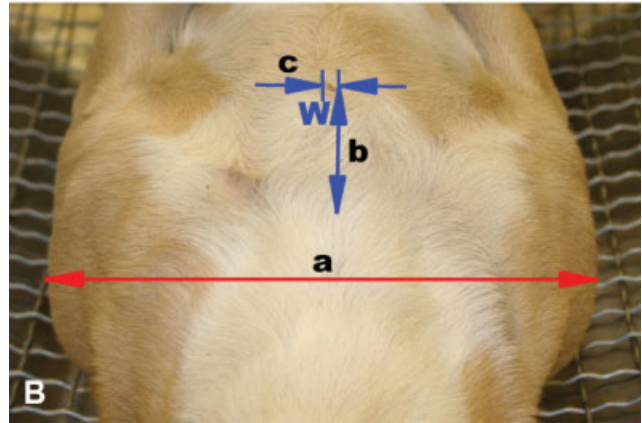
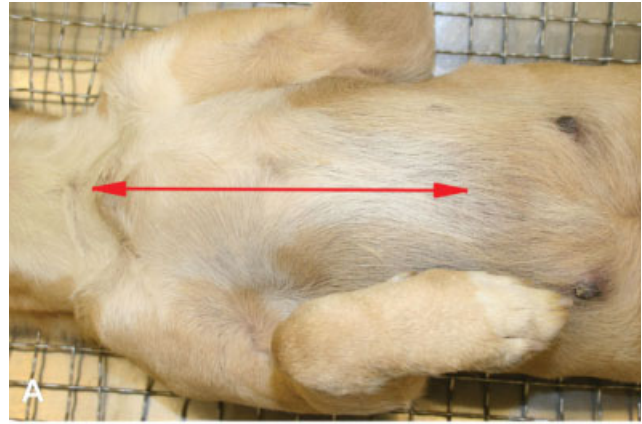


Fig. 6. Chest whorl (w) measurement. **A:** Distance measured from the cranial end of the manubrium to the caudal limit of the xiphoid process. **B:** Chest whorl (w) measurement; (a) width between the acromion processes of the two scapulae; (b) distance of the whorl from a transverse line at the level of the manubrium; and (c) lateral distance of the whorl from the midline.

caudal limit of the xiphoid process (Fig. 6A). Whorls were assessed and measured laterally from the midline, and longitudinally from a transverse line at the level of the cranial end of the manubrium (Fig. 8).

Shoulder whorls. Position of shoulder whorls was determined as the distance from the cranial tip of the greater tubercle of the humerus, and the medial or lateral distance from the brachial midline (Fig. 9).

Elbow whorls. Elbow whorls are situated over the olecranon. Whorl position was assessed on both limbs as the distance from the most caudal point of the olecranon (Fig. 10), and then its position in relation to the olecranon, so recorded as distal or proximal, medial, or lateral.

Abdominal whorls. Standard measurements for assessment of abdominal whorls were (i) width between the lateral most aspect of the 10th rib, and (ii) distance from the caudal limit of the xiphoid process to the anus. Whorl position was measured as the longitudinal distance from a transverse line at the level of the xiphoid process, and laterally from the midline (Fig. 11). Position

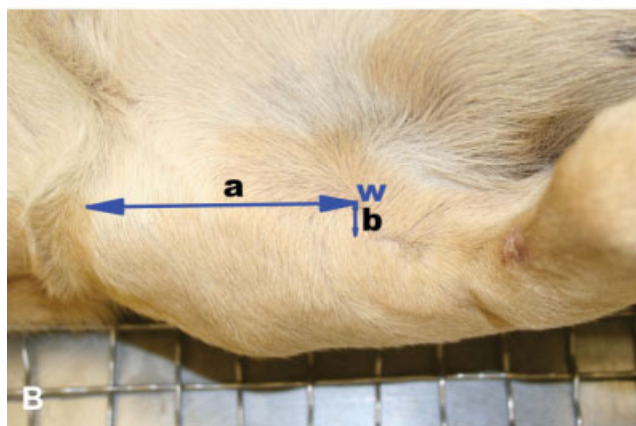
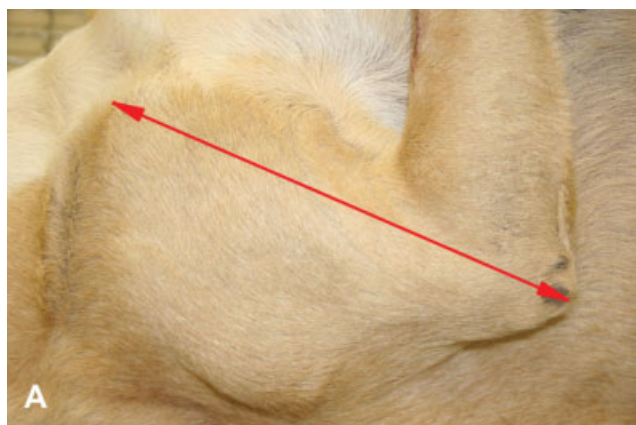


Fig. 7. Brachial axillary whorl measurement. **A:** Distance measured from the tip of the greater tubercle to the most caudal point of the olecranon. **B:** Measurement of brachial axillary whorls (w); (a) distance from the greater tubercle of the humerus; and (b) distance from the cranial midline of the brachium.

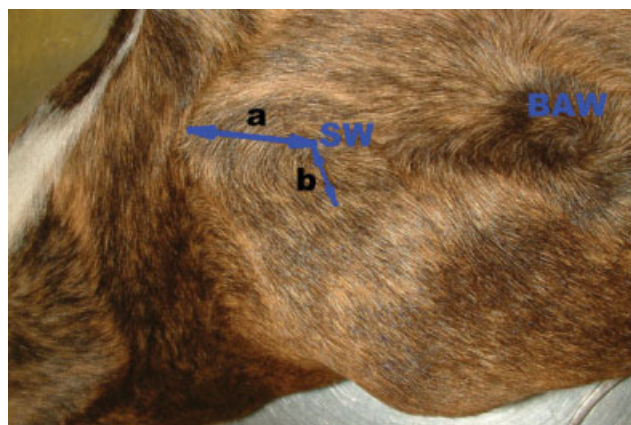


Fig. 9. Shoulder whorl (SW) measurement; (a) distance from the cranial tip of the greater tubercle of the humerus; and (b) distance from the brachial midline. BAW, brachial axillary whorl.

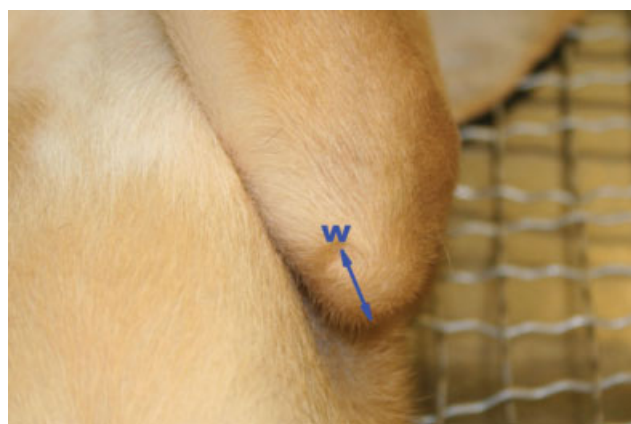

Fig. 10. Elbow whorl measurement; distance from the olecranon to the elbow whorl (w).

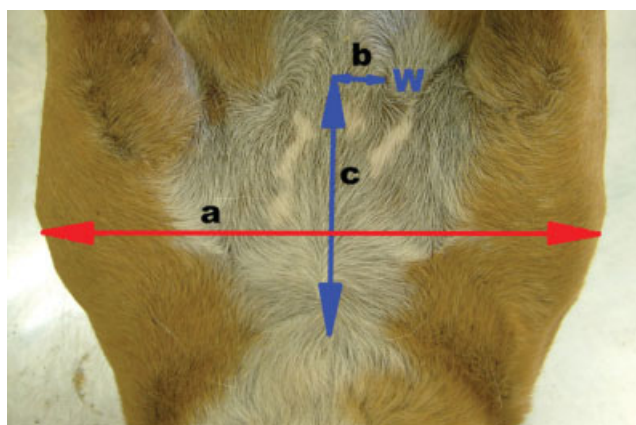


Fig. 8. Thoracic axillary whorl (w) measurement; (a) distance measured from the cranial end of the manubrium to the caudal limit of the xiphoid process; (b) laterally from the midline; and (c) from a transverse line at the level of the manubrium.

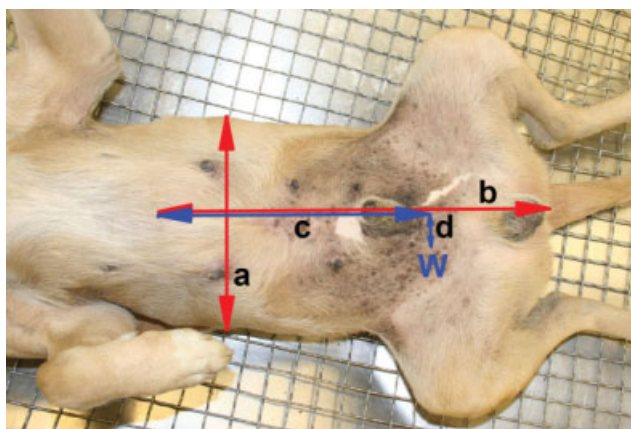


Fig. 11. Abdominal whorl measurement; (a) width between the lateral most aspect of the 10th rib; (b) distance from the caudal limit of the xiphoid process to the anus; and whorl (w) distance measured (c) longitudinally from a transverse line at the level of the xiphoid process, and (d) laterally from the midline.

was also recorded as left or right of the midline from a ventral aspect.

Ischiatic whorls Bilateral ischiatic whorls are present on the caudal aspect of the thigh in the region of the tuber ischii. The width between the caudal limits (medial angles) of the left and right tuber ischii was measured for standardization. Distances of the whorl from the caudal limit of the tuber ischii, and from the midline (Fig. 12), were recorded. To enable comparison between dogs, the position of left and right ischiatic whorls were described as distance ratios from the tuber ischii. Position in relation to the tuber ischii was also noted; where it was either dorsal or ventral, and medial or lateral to the tuber ischii.

Coat Length and Thickness

Coat length and density were categorized post-sampling from photographs of the original specimens. *Post hoc* data collection for these attributes was used because, prior to the study, there was no knowledge of the variety, and hence, the categories, of coat types which would be presented. Dogs with hair coat 2 cm and less in length were classified as short-haired dogs, and those above 2 cm were classified as long-haired dogs. Thickness of the coat was classified as thin, medium, or dense, based on the ratio of primary (guard) and secondary (undercoat) hairs. The ratio of these two types of hairs differs between breeds where breeds such as Sibe-

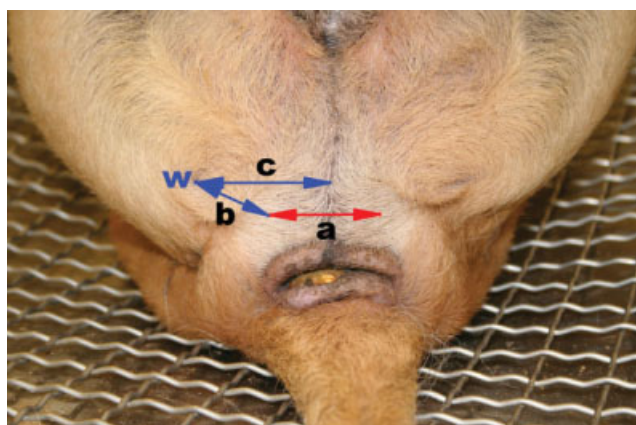


Fig. 12. Ischiatic whorl (w) measurement; (a) width between the caudal limits of the left and right tuber ischii; (b) distance of the whorl to the caudal limit of the tuber ischii; and (c) from the whorl to the midline.

rian Huskies, have a higher ratio of secondary-to-primary hair than Dalmatians whose hair coat consists mainly of primary hairs. Key differences in the secondary-to-primary hair ratio are reflected in the differences that were most readily observable in our photographs of the thoracic region of the dogs where skin could be observed between the individual hair shafts of fine-coated dogs, but not between those of dense-coated dogs. Since coat characteristics were assessed *post hoc*, the breed (or probable cross) of the dog as recorded at whorl assessment was used in conjunction with the photographs to categorize each dog's coat length and thickness. Common breeds for each of the hair characteristic categories can be seen in Table 2. The abundance of secondary hairs within adult dog hair-coats seems to be associated with the length of hair, given that short-haired dogs generally do not exhibit undercoats. Therefore, there are typically no breeds that exhibit short-haired, dense hair coats.

A sub-sample of randomly selected dogs (N = 30) was reviewed by two observers to determine inter-observer reliability of assessing coat characteristics based on the criteria outlined in the above methodology. A computer-generated list of random numbers was used for this selection.

Statistical Analysis

The statistical package GenStat 10th Edition (VSN International; Hemel Hempstead, UK) was used for all whorl analyses. Hair whorl position was analyzed using an unbalanced analysis of variance, and binomial logistic regression was used to analyze whorl presence. Four predictor variables (sex, source, coat length, and coat thickness) were assessed in both models. To determine if whorl position on the left and right sides of the dog's body were associated, a simple Pearson correlation test (Pearson's product-moment correlation coefficient = r) was performed. A one sample t test was used to determine biases of whorl position on the lateral-medial and proximal-distal axes. Dogs that had multiple hair whorls in a single region and on the one side were recorded, but not included within the analysis. This included the exclusion of dogs from the ventral mandibular (N = 2), thoracic axillary (N = 2), and brachial axillary (N = 1) whorl analyses. The exclusion of animals with such whorls from statistical analysis follows the precedent reported in cattle (Evans et al., 2005) and horse (Murphy and Arkins, 2004; Górecka et al., 2006) studies. Inter-observer reliabilities for coat length and coat thickness were determined using a kappa test from the statistical package Minitab 15th Edition (Minitab; PA).

TABLE 2. Breeds of dog typically associated with different coat characteristics

Coat length	Coat thickness		
	Fine	Medium	Dense
Short	Dalmatian	Beagle	—
	Grayhound	Fox Hound	—
	American Staffordshire Terrier		—
Long	Maltese	Border Terrier	German Shepherd Dog
	Irish Wolfhound	Irish Water Spaniel	Australian Cattle Dog
	Cocker Spaniel		Siberian Husky

TABLE 3. Presence and classification of whorls occurring bilaterally

Position	Presence [%] (N)			Classification [%] (N)	
	Overall	Right	Left	Simple	Tufted
Cephalic	5.00 (6)	5.00 (6)	5.00 (6)	100.00 (12)	0.00 (0)
Cervical–Dorsal	0.00 (0)				
Cervical–Lateral ^a	11.67 (14)	8.40 (10)	7.56 (9)	100.00 (19)	0.00 (0)
Brachial Axillae ^a	90.76 (108)	88.24 (105)	87.39 (104)	100.00 (209)	0.00 (0)
Thoracic Axillae ^b	19.49 (23)	14.41 (17)	15.25 (18)	100.00 (35)	0.00 (0)
Shoulder	3.33 (4)	1.67 (2)	2.50 (3)	100.00 (5)	0.00 (0)
Elbow	85.00 (102)	81.67 (98)	82.50 (99)	0.00 (0)	100.00 (197)
Abdominal	2.50 (3)	2.50 (3)	2.50 (3)	100.00 (6)	0.00 (0)
Ischiatic	80.00 (96)	80.00 (96)	80.00 (96)	98.96 (190)	1.04 (2)

The percentage of dogs with whorls present in each region are based on $N = 120$, with the exception of ^a $N = 119$, ^b $N = 118$.

TABLE 4. Presence and classification of whorls occurring centrally

Position	Presence [%] (N)	Classification [%] (N)	
		Simple	Tufted
Ventral Mandibular ^a	19.47 (22)	100.00 (22)	0.00 (0)
Chest	75.83 (91)	3.30 (3)	96.70 (88)

The percentage of dogs with whorls present in each region are based on $N = 120$, with the exception of ^a $N = 113$.

RESULTS

Hair whorls were located in 10 of the 11 different locations investigated in domestic dogs, and the presence and classification for bilateral and centrally located whorls appear in Tables 3 and 4, respectively. No whorls were observed on the dorsal surface of the cervical region. Whorls that occurred on both sides of the body in one region were not always present in equal frequencies on the left and right sides. Cephalic, abdominal, and ischiatic whorls were bilateral, with equal frequencies occurring on both the left and right side of the animal. In contrast, in other regions, such as cervical (lateral), brachial axillae, thoracic axillae, shoulders, and elbow regions, whorls occurred with differing frequencies on the left and right side of the dogs' bodies.

The frequency of whorls present also differed significantly between different locations. The regions where whorls were present in less than 10% of dogs [cephalic, cervical (dorsal and lateral), shoulder, and abdominal regions] were excluded from the analysis, as there were insufficient data available to determine the factors affecting the outcome.

Cephalic Whorls

Cephalic whorls were present in only 5.00% of dogs in this sample. They were bilateral, and were consistently classified as simple. Since cephalic whorls were present only in a small proportion of dogs, limited analysis was performed. On the right side of the head, whorls on average were 23.44% from the occiput and 89.02% from the midline. On the left side, whorls on average were 22.10% from the occiput and 91.78% from the midline.

The distance of the cephalic whorl from the midline was negatively correlated to its distance from the occiput on both the left ($r = -0.934$; $P = 0.006$) and right ($r = -0.896$; $P = 0.016$) side of the head. The distances of the whorl from the occiput on both the left and right sides were positively correlated ($r = 0.983$; $P = 0.0004$) with one another, as were the distances from the midline on both sides ($r = 0.978$; $P = 0.0007$).

Cervical Lateral Whorls

As mentioned previously, no whorls were observed on the dorsal surface of the cervical region. Whorls were present on the lateral surfaces of the neck, but in differing percentages on the alternate sides. Although lateral cervical whorls were present only on the left side of the neck in 8.40% of dogs, and in 7.56% on the right side, overall, 11.67% of dogs had at least one whorl in the lateral cervical region. Of these dogs, 35.71% of dogs had a whorl on both the left and right side of the neck. Whorls were consistently classified as simple. Left lateral cervical whorls on average were 30.48% of the distance from the occiput, 57.15% distance from the midline, and were not significantly correlated with each other ($r = -0.357$; $P = 0.346$). On the right side, whorls on average were 33.81% from the occiput, 56.87% from the midline, and were also not significantly correlated with each other ($r = -0.267$; $P = 0.456$).

Ventral Mandibular Whorls

Ventral mandibular whorls were present in 19.47% of dogs assessed. Dogs with only a single whorl in the ventral mandibular region primarily had whorls on the left side of the body (86.67%), compared with the 13.33% of dogs with a whorl on the right. A portion (5.83%) of the current population had two whorls, with 71.43% of these dogs having a whorl on both sides of the midline, and only 28.57% of dogs with two ventral mandibular whorls having both whorls on the same (right) side of the body. The presence of a ventral mandibular whorl was not significantly associated with coat length ($P = 0.921$) or thickness ($P = 0.933$), source ($P = 0.677$), or sex ($P = 0.082$) of the dog. Interspecies consistency was observed in the classification of ventral mandibular whorls, with 100% of whorls being simple. Ventral mandibular whorls were positioned on the left side of the dog more

frequently than on the right ($P = 0.017$), with the average position of the whorl being 23.54% of the distance to the left side of the dog's ventral midline. Whorls on average were located cranially 51.82% of the distance from the thoracic inlet (TI), and were positively correlated with whorl position along the midline axis ($r = 0.657$; $P = 0.007$).

Chest Whorls

Chest whorls were present in 75.83% of dogs tested, with the majority of whorls being classified as tufted (96.70%) and not simple (3.30%). Presence of a whorl on the dog's chest was not significantly associated with either the dog's sex ($P = 0.908$) or coat thickness ($P = 0.186$). Both source ($P < 0.001$) and coat length ($P < 0.001$) were significantly associated with the occurrence of whorls. Compared with dogs sourced from a home environment (non-sheltered), shelter dogs had significantly more whorls on the chest (58.24% vs. 41.76%), and short-haired dogs had significantly more than long-haired dogs (92.00% vs. 51.16%). Chest whorls were located on the right side of the midline more frequently than on the left ($P = 0.050$), with the average position of the whorl being 0.98% of the distance to the right of the dog's midline. Whorls on average were caudally located 6.97% of the distance from the TI, with a 95% confidence interval of 5.94%–8.00%. The positions of whorls along the TI axis and from the midline axis were not significantly correlated ($r = -0.100$; $P = 0.344$), enabling position along both axis to be analyzed independently. Whorl position in relation to the midline was not significantly associated with coat length ($P = 0.119$) or thickness ($P = 0.169$), source ($P = 0.718$), or sex ($P = 0.922$) of the dog. Position in relation to the TI was not significantly associated with coat length ($P = 0.139$) or thickness ($P = 0.620$), or sex ($P = 0.661$) of the dog, but a tendency towards significance was observed for source ($P = 0.056$). Dogs sourced from shelters had whorls that were on average 6.72% of the distance from the TI, whereas non-shelter dogs had whorls that were 4.99% from the TI.

Thoracic Axillary Whorls

The presence of a whorl in the thoracic axillary region differed on the right (14.41%) and left (15.25%) side of the thorax. Overall, 19.49% of dogs tested had at least one whorl within this region, with 52.17% of these dogs having a whorl on both the left and right side of the thorax. All whorls observed in the thoracic axillary region were classified as simple. The presence of a whorl on the left or right side of the thoracic region was not significantly associated with coat length [Right (R), $P = 0.751$; Left (L), $P = 0.337$] or thickness (R, $P = 0.944$; L, $P = 0.596$), sex (R, $P = 0.956$; L, $P = 0.895$), or source (R, $P = 0.893$; L, $P = 0.256$) of the dog. Left thoracic axillary whorls (TAW) on average were 28.07% of the distance from the TI, 32.71% from the midline, and were not significantly correlated ($r = 0.070$; $P = 0.783$). On the right side, whorls on average were caudally located 27.08% of the distance from the TI and 38.63% from the midline, and were also not significantly correlated with each other ($r = -0.290$; $P = 0.258$). The position of a TAW on the right side of the thorax was not significantly

associated with coat thickness [from the thoracic inlet (TI), $P = 0.639$; from the dog's midline (Mid), $P = 0.174$], sex (TI, $P = 0.377$; Mid, $P = 0.514$) or source (TI, $P = 0.214$; Mid, $P = 0.534$) of the dog. Coat length was not significantly associated with the distance of a whorl from the midline ($P = 0.242$), but showed a tendency to influence the distance from the TI ($P = 0.074$), where long-haired dogs had whorls that were on average 29.15% of the distance from the TI, whereas short-haired dogs had whorls that were 25.63% from the TI. The position of a TAW on the left side of the thorax was not significantly associated with the sex of the dog (TI, $P = 0.159$; Mid, $P = 0.492$), and the distance from the midline was not significantly associated with coat thickness ($P = 0.327$) or source of the dog ($P = 0.224$). Coat length was significantly associated with the distance of a whorl from the both the TI ($P = 0.033$) and the midline ($P = 0.033$). Compared with short-haired dogs, long-haired dogs had whorls that were further from the TI (41.89% vs. 24.12%) and were closer to the midline (29.53% vs. 33.62%). The position of the whorl from the TI also showed a tendency to be associated with the source of the dog (non-shelter, 23.61%; shelter, 35.07%; $P = 0.055$), and coat thickness (dense, 17.21%; medium, 38.66%; fine, 27.18%; $P = 0.089$).

Brachial Axillary Whorls

The presence of brachial axillary whorls (BAW) differed on the right (88.24%) and left (87.39%) thoracic limb. Of the dogs tested, 90.76% exhibited at least one BAW, and 93.52% of these dogs had a whorl on both their left and right thoracic limb. The presence of a BAW on the left or right thoracic limb was not significantly associated with coat length (R, $P = 0.252$; L, $P = 0.203$) or thickness (R, $P = 0.357$; L, $P = 0.798$), sex (R, $P = 0.738$; L, $P = 0.309$), or source (R, $P = 0.088$; L, $P = 0.088$) of the dog. All BAWs were classified as simple. Left BAWs on average were 42.23% of the distance from the shoulder joint, 43.60 mm from the midline, and were not significantly correlated ($r = -0.121$; $P = 0.222$). On the right side, whorls on average were caudally located 43.23% of the distance from the shoulder joint, 43.05 mm from the midline, and were positively correlated with each other ($r = 0.302$; $P = 0.002$). BAWs occurred more frequently on the medial side of the midline, and not laterally on both the left ($P < 0.001$) and right ($P < 0.001$) thoracic limb. The position of a BAW on the right thoracic limb was not significantly associated with coat thickness [from the shoulder joint (SJ), $P = 0.981$; Mid, $P = 0.829$] and the distance from the shoulder joint was not significantly associated with sex ($P = 0.986$) or source of the dog ($P = 0.219$). Coat length was significantly associated with the whorl's distance from the shoulder joint ($P = 0.040$), but not from the midline ($P = 0.361$). Long-haired dogs had whorls that were on average 45.46% of the distance from the shoulder joint compared with short-haired dogs that had whorls that were 42.01% from the shoulder joint. The position of the whorl from the midline was also significantly associated with sex (male, 36.41 mm; female, 50.35 mm; $P = 0.018$), and source (non-shelter, 60.61 mm; shelter, 27.68 mm; $P < 0.001$) of the dog. The position of a BAW on the left thoracic limb was not significantly associated with coat thickness (SJ, $P = 0.905$; Mid, $P = 0.916$), and the

distance from the shoulder joint was not significantly associated with sex ($P = 0.915$) or source ($P = 0.456$) of the dog. Coat length was significantly associated with the distance of the whorl from the shoulder joint ($P = 0.021$), and showed a tendency to from the midline ($P = 0.079$). Long-haired dogs had whorls that were on average 51.05 mm distance from the midline, and 45.86% from the shoulder joint compared with short-haired dogs that had whorls that were 37.29 mm from the midline, and 42.33% of the distance from the shoulder joint. The distance of the whorl from the midline was also significantly associated with sex (male, 35.28 mm; female, 50.85 mm; $P = 0.031$) and source (non-shelter, 58.62 mm; shelter, 28.48 mm; $P < 0.001$).

Shoulder Whorls

Whorls were present on the shoulder of the dog, but in differing percentages with the alternate sides. Although whorls were present only on the left shoulder in 2.50% of dogs, and in 1.67% on the right shoulder, overall, 3.33% of dogs had at least one whorl in the shoulder region. Of these dogs, only 25.00% had a whorl on both the left and right shoulder, with 75.00% of dogs having only one whorl on either of their shoulders. Whorls were consistently simple in their classification. Whorls on average were positioned 18.62% of the distance from the shoulder joint on the left thoracic limb, and 20.04% on the right thoracic limb, and from the midline were 123.33 mm on the left and 185.00 mm on the right.

Elbow Whorls

Elbow whorls were present in 85.00% of dogs assessed. Presence of a whorl on the left (82.50%) and right (81.67%) elbow differed slightly. The presence of an elbow whorl on the left or right thoracic limb was not significantly associated with coat thickness (R, $P = 0.059$; L, $P = 0.079$) or sex (R, $P = 0.365$; L, $P = 0.555$) of the dog. Coat length (R, $P = 0.010$; L, $P < 0.001$) and source (R, $P = 0.002$; L, $P < 0.001$) of the dog was significantly associated with the presence of a whorl located on the left or right elbow. Compared with non-shelter dogs, dogs sourced from shelters had significantly more whorls on both the left (58.59% vs. 41.41%; $P < 0.001$) and right (57.14% vs. 42.86%; $P = 0.002$) elbows. Similarly, short-haired dogs had significantly more whorls than long-haired dogs on both the left (68.69% vs. 31.31%; $P < 0.001$) and right (67.35% vs. 32.65%; $P = 0.010$) elbows. All elbow whorls were classified as tufted. The distance of the elbow whorl from the olecranon on the left (79.60 mm) and right (84.74 mm) elbow differed slightly. The distance of a whorl from the olecranon on the left or right arm was not significantly associated with coat length (R, $P = 0.426$; L, $P = 0.804$) or thickness (R, $P = 0.113$; L, $P = 0.548$), sex (R, $P = 0.114$; L, $P = 0.949$) or source (R, $P = 0.538$; L, $P = 0.101$) of the dog. The distance of the whorl on both the left and right elbows was not significantly correlated to the location of the whorl on the proximal-distal axis (R, $r = -0.073$, $P = 0.477$; L, $r = -0.104$, $P = 0.305$) or the medial-lateral axis (R, $r = -0.049$, $P = 0.631$; L, $r = -0.099$, $P = 0.331$), and the two axes were independent (R, $r = -0.063$, $P = 0.543$; L, $r = 0.066$, $P = 0.514$). Whorls were more likely to be located distally ($P < 0.001$) and

laterally ($P < 0.001$) rather than proximal and medial on both the left and right elbows.

Abdominal Whorls

Abdominal whorls were present in only 2.50% of dogs assessed and were consistently simple in their classification. Whorls were bilateral, with equal distribution on the left and right side of the abdomen. Whorls on average were positioned 72.77% of the distance from the caudal limit of the xiphoid process on the left side, and 68.80% on the right side, and from the midline were 20.34% of the distance on the left and 22.00% on the right.

Ischiatic Whorls

Ischiatic whorls were bilateral and present in 80.00% of the assessed population. The presence of a left or right ischiatic whorl was significantly associated with coat length; short-haired dogs being more likely to have a whorl present than long-haired dogs on both the right (93.33% vs. 57.78%; $P < 0.001$) and left (93.33% vs. 57.78%; $P < 0.001$) ischiatic region. Coat thickness showed a tendency to influence the presence of a left or right ischiatic whorl with fine-coated dogs having a whorl present more often than dogs with dense coats on both the right (fine, 94.44%; medium, 76.47%; dense, 59.38%; $P = 0.084$) and left (fine, 94.44%; medium, 76.47%; dense, 59.38%; $P = 0.084$) sides. The occurrence of a left or right ischiatic whorl was not significantly associated with sex (R, $P = 0.214$; L, $P = 0.214$), or source (R, $P = 0.160$; L, $P = 0.160$) of the dog. Little variation occurred in the classification of ischiatic whorls, with 98.96% being simple, and only 1.04% being tufted. The position of an ischiatic whorl from the midline was 268.5 mm on the right and 277.2 mm on the left side. The ratio of the distance of the whorl from the tuber ischii was 1.930 on the right and 1.963 on the left side. Both the position of a whorl from the midline, and as a ratio from the tuber ischii, were positively correlated on the right ($r = 0.816$; $P = 0.000$) and left ($r = 0.858$; $P = 0.000$) sides.

Inter-Observer Reliability

Results demonstrated 93.33% inter-observer reliability for both coat length (Kappa coefficient = 0.857) and coat thickness (Kappa coefficient = 0.891).

DISCUSSION

Considerable variability in hair characteristics such as hair length, thickness, and color exists among the various breeds of dogs, as well as between individual dogs within these breeds. Therefore, it stands to reason that there is also some variability in hair whorl characteristics between dogs. The similar distribution of females and males used in this study, a ratio of 1:1.1, suggests that this randomly selected dog cohort is representative of the Australian dog population.

Whorl Classification

It was found that the classification of whorls varied with the region of the body in which they were located.

Whorls located in the cephalic, cervical, brachial and thoracic axillary, shoulder, and abdominal regions were all simple, as were the majority of whorls in the ischiatic region. Tufted whorls were less common than simple whorls, with only elbow whorls being solely of this classification, and the majority of chest whorls being tufted. Overall, the majority of whorls located on dogs were simple. This, in part, can be attributed to patterning and direction of hair over the dog's body. Hair diverges largely from whorls, but after assessing hair whorl characteristics in this cohort of dogs, it became apparent that, beyond tufted converging whorls, there are numerous ways in which hair can terminate. These include the hair growing in opposing directions and meeting to form a ridge, as demonstrated on the palmar surface of the antebrachial region of the thoracic limbs. Alternatively, the integument changes in certain parts of the body as it makes a transition from skin to mucous membrane or keratinized pad. There are numerous alternatives for hair patterning to cease other than a tufted whorl, yet very few alternatives for hair emergence other than a simple whorl. This helps to explain why the majority of whorls on the assessed dog population are simple and not tufted.

Although it is generally accepted that hair patterning is determined during fetal development (Smith and Gong, 1974), there is little consensus on the underlying mechanisms of whorl formation. A number of established developmental theories explain whorl formation, including both environmental and genetic. Based on Colin's (1943) theory of metabolic activity controlling whorl characteristics, the center of a converging whorl (e.g., the tufted elbow and chest whorl) should represent regions of high metabolic activity. Subsequent studies may be able to utilize the current methodological framework to test Colin's developmental theory using comparative metabolic activity studies between the tufted elbow and chest whorls and simple whorls. Another theory that has recently added to this developmental debate surrounds expression of the Frizzled-6 (Fz6) gene. Researchers have shown that in mice, the Wnt signaling pathway and the Frizzled-6 gene play a role in hair patterning, with targeted deletion of the gene resulting in an abundance of hair whorls on the hind feet and head (Guo et al., 2004; Wang et al., 2006). Consequent studies in dogs may involve labeling cells *in situ* for Frizzled-6 to identify this gene's role in whorl development. Although the direct mechanism that initiates the presence of a whorl is unknown, the distribution of these whorls in dogs and the presence within a given population can be assessed using the current approach.

Whorl Presence

The current study has shown that whorls in dogs arise in a variety of anatomical positions including on the head (cephalic), neck (cervical lateral and ventral), thorax (chest and thoracic axillary), thoracic limbs (brachial axillary, shoulder, and elbow), abdomen, and on the caudal thighs (ischiatic whorls).

Whorls located on the chest, brachial axillary region, elbows, and caudal thighs were seen in the majority of the current cohort, and so are considered typical. Atypical whorls are those that did not occur in the majority of dogs, and so represent a variation from normal hair pat-

terning. Whorls in atypical regions included those on the head, cervical regions (dorsal, ventral, and lateral), shoulders, the thoracic axillary region, and on the ventral abdominal region, where whorl presence was a feature of fewer than 20% of the population. However, when assessing dogs for hair whorls, it is important to assess each subject for the presence of all whorls, including those which are atypical since these may turn out to be critical in identifying potential relationships with other traits of interest, such as behavior. None of the dogs in the current population had whorls on the dorsal aspect of the neck. However, it was anticipated that had a Rhodesian Ridgeback been included within the study, at least one whorl in this region would have been seen. Previous observations suggest that dorsal whorls in the cervical-thoracic region are most likely to be the result of a ridge. A whorl may form at the cranial or caudal end of a ridge, and when in this position, could be either tufted or simple. It was also interesting to note that cephalic whorls occurred only on the lateral surfaces of the face, and did not appear on the frontal, parietal, or occipital regions of the integument over the cranium.

Whorls were located bilaterally in the cephalic, abdominal, and ischiatic regions in equal frequencies, and on the thoracic limbs (brachial axillary, shoulder, and elbow) and the thoracic axillary region in unequal frequencies. Discrepancies between the presence of whorls on the left and right elbows were due to some dogs having hair loss and replacement with calluses on one elbow, but the presence of a whorl on the alternate elbow. The absence of equal frequencies in the other regions of the body cannot be attributed to such wear-and-tear that arises because of behavioral asymmetries. Frequencies between the left and right sides were similar, but differences arose due to some dogs having only a brachial axillary or shoulder whorl on just one thoracic limb. Whorls also occurred on both the left and right lateral surface of the neck. These whorls were not bilateral, and occurred on both sides of the neck in only 35.71% of dogs that had a lateral cervical whorl.

Chest and ventral mandibular whorls were located centrally; typically at the rate of only one whorl per region. As such, these whorls were not bilateral. They were recorded as being to the left or right of the midline. In some cases (5.83%), more than one whorl occurred in the ventral mandibular region. Of these dogs, only a few (28.57%) had whorls that were on the same side of the midline (right side of the dog), whereas in most dogs (71.43%) they were on opposite sides. Less than 20% of the population tested had ventral mandibular whorls, making whorls in this region atypical, as mentioned previously.

The distribution of whorls throughout certain locations varied considerably. The majority of dogs had chest, brachial axillary, elbow, and ischiatic whorls. Although whorls could not be located in these positions for all dogs, the authors accept that in some long-haired dogs (18 of the 45 long-haired dogs) failure to detect whorls was largely a result of these dogs having such long hair that manipulation and detection of the whorl was rendered too difficult to detect any whorl. The palpation and hair-cluster method described here is best suited to dogs with hair coats that are short-to-medium in length, and which are not excessively dense. It will meet with only limited success in dogs with long, thick, dense coats

such as Malamutes, Siberian Huskies, and German Shepherd Dogs. Since the presence of a whorl is established *in utero* and does not change with age, hair whorl characteristics in such dogs could be assessed prior to maturation while the hair coat is shorter. That said, whorl position will most likely change to some extent with the development of muscle and the lengthening of bones as pups grow, so comparative studies between adults and pups for whorl position would help to quantify differences that result from maturation. Alternatively, clipping of long hair may increase visibility of the whorl, but its usefulness will depend on the thickness of the dog's coat and on the willingness of the participating dog owners to have their dogs clipped.

It was also interesting to note that the source of the dog was associated with the presence of some whorls. Compared with non-shelter dogs, those sourced from shelters had significantly more whorls on the chest (58.24% vs. 41.76%; $P < 0.001$) and elbow (56.86% vs. 43.14%; $P < 0.001$). Salman et al. (2000) reported that behavioral problems, including aggression, was the predominant cause of owners relinquishing dogs to shelters. Given that the cadavers had been sourced from a shelter and that dogs in shelters have usually either strayed or have been surrendered for behavioral reasons, the relationship between source and hair whorls was of interest because it may elucidate whether the presence of a whorl is an indicator of an undesirable behavioral trait.

The relationship between the two characteristics has been explored by a number of studies across species. For example, the relationship between facial whorl position in cattle and temperament has been well documented (Grandin et al., 1995; Randle, 1998; Lanier et al., 2001), with the location of forehead whorls relative to the medial canthi of the eyes being predictive of reactivity. The relationship between hair patterns and behavioral reactivity can be attributed to the nervous system and skin products sharing a common ectodermal embryonic origin; the ectoderm (Smith and Gong, 1974). This offers a premise for investigating the potential relationship between hair whorls and behavior.

Further studies should investigate whether whorls on the chest and elbow regions of dogs are associated with certain unfavorable behavioral attributes. By developing a methodology to assess the whorl characteristics in the domestic dog, the current data offers the potential to facilitate exploration of the relationship between behavior and hair whorl characteristics.

Whorl Position

Breed and individual differences in muscle mass, subcutaneous fat deposits, or the state of rigor mortis could affect whorl position measurements by causing the skin to become more or less fixed to subcutaneous structures. Because of this variation and the flexibility of the integument at various regions assessed, all dogs were assessed for whorls in the same position, the exception being ischiatic whorl assessment. For this reason, the only exclusion criteria applied during cadaver selection were those designed to avoid the effects of rigor mortis: only fresh cadavers (less than 4 hr post-euthanasia) were assessed. To reduce breed and individual differences in bone structure, muscle mass, or fat deposits, position was expressed as a percentage distance away from

a bony landmark. Despite these precautions, the source of the dog was significantly associated with numerous differences in whorl position; e.g., position of the chest whorl from the TI and the left and right BAW from the midline. Given these whorls were assessed on dogs in the same position regardless of their source, rigor mortis and the position of the dog could not be responsible for the variation.

Sex of the dog was significantly associated with the position of the left and right BAW from the midline. Male dogs had whorls positioned closer to the midline, which may be a result of females having a higher proportion of subcutaneous fat than males, and their predisposition to being overweight or obese (McGreevy et al., 2005).

There was also a trend towards significance for coat thickness affecting whorl position, whereby animals with dense coats had their left TAW positioned closer to the TI than dogs with finer coats. Coat thickness is largely determined by the diameter and quantity of hair fibers present in the skin. Hair fibers develop from dermal papillae cells within the skin, and the distribution of these cells within the mesenchyme ultimately determines fiber diameter and quantity (Moore et al., 1998). The developmental mechanisms associated with dermal papillae distribution in the mesenchyme have not been determined, but the current finding that TAW position differed in animals with denser coats supports the view that cell signalling involved in dermal papillae distribution may also signal areas for whorl placement.

A number of whorl positions in the thoracic region were significantly associated with coat length. Longer-haired dogs had left TAWs that were further from the TI than shorter-haired dogs, a tendency also observed for right TAWs. On the left TAW, whorls were closer to the midline in longer-haired dogs. For the left and right BAWs, longer-haired dogs had whorls further away from the shoulder joint than short-haired dogs, and there was a tendency for the left BAW to be further from the midline in longer-haired dogs. Genetic factors control the length of the anagen phase in the hair cycle (Arslan et al., 1983), and hence, the length of hair in dogs of different breeds. The significant association observed in this study between hair coat length and whorl position suggests that these genetic factors responsible for altering the length of anagen may also influence the position of whorls in the axillary regions.

As mentioned earlier, the exact mechanisms that control whorl development remain unclear. Therefore, any theory to explain the association between factors such as sex or source of the dog, coat length or thickness, with brachial and thoracic axillary whorl position is largely speculative. Although the composition of the current cohort was considered representative of the Australian domestic dog population, further studies may clarify the influence of coat length and thickness on whorl position.

This novel study offers a palpation and hair-cluster method of assessment to classify canine hair whorl characteristics and a system for relating whorl position to relevant bony landmarks within each region. The whorl classification method is best suited to dogs with short-to-medium length hair coats, which are not excessively dense. Typical whorls were located on the chest, brachial axillary region, elbows, and caudal thighs (ischiatic), and atypical whorls located on the head (cephalic),

cervical regions (dorsal, ventral, and lateral), shoulders, thoracic axillary region, and on the ventral abdominal region.

ACKNOWLEDGMENTS

The authors thank Jane Stevenson for her anatomical assistance and Associate Professor Peter Thomson for his statistical advice.

Literature Cited

- Arslan SH, MacKenzie ICP, Brown R, Baxter JT. 1983. The phase of hair growth in hypothyroidism in the dog. *Vet Res Commun* 6:51–58.
- Colin EC. 1943. Hair direction in mammals: embryogenesis of hair follicles in the guinea pig. *J Morphol* 72:191–223.
- Evans RD, Grandin T, DeJarnette JM, Deesing M, Garrick DJ. 2005. Phenotypic relationships between hair whorl characteristics and spermatozoal attributes in Holstein bulls. *Anim Reprod Sci* 85:95–103.
- Górecka A, Golonka M, Chruszczewski M, Jezierski T. 2007. A note on behavior and heart rate in horses differing in facial hair whorl. *Appl Anim Behav Sci* 105:244–248.
- Górecka A, Sloniewski K, Golonka M, Jaworski Z, Jezierski T. 2006. Heritability of hair whorl position on the forehead in Konik horses. *J Anim Breed Genet* 123:396–398.
- Grandin T, Deesing MJ, Struthers JJ, Swinker AM. 1995. Cattle with hair whorl patterns above the eyes are more behaviorally agitated during restraint. *Appl Anim Behav Sci* 46:117–123.
- Guo N, Hawkins C, Nathans J. 2004. Frizzled6 controls hair patterning in mice. In: *Proceedings of the National Academy of Sciences of the United States of America*. Vol. 101: p 9277–9281.
- Gworys B, Domagala Z. 2003. The typology of the human fetal lanugo on the thorax. *Ann Anat* 185:383–386.
- Jansen A, Lohmann H, Scharfe S, Sehlmeier C, Deppe M, Knecht S. 2007. The association between scalp hair-whorl direction, handedness and hemispheric language dominance: is there a common genetic basis of lateralization? *NeuroImage* 35:853–861.
- Klar AJ. 2003. Human handedness and scalp hair-whorl direction develop from a common genetic mechanism. *Genetics* 165:269–276.
- Klar AJ. 2005. A 1927 study supports a current genetic model for inheritance of human scalp hair-whorl orientation and hand-use preference traits. *Genetics* 170:2027–2030.
- Lanier JL, Grandin T, Green R, Avery D, McGee K. 2001. A note on hair whorl position and cattle temperament in the auction ring. *Appl Anim Behav Sci* 73:93–101.
- McGreevy PD, Thomson PC, Pride C, Fawcett A, Grassi T, Jones B. 2005. Prevalence of obesity in dogs examined by Australian veterinary practices and the risk factors involved. *Vet Rec* 156:695–702.
- Meola MG, Grandin T, Burns P, Deesing M. 2004. Hair whorl patterns on the bovine forehead may be related to breeding soundness measures. *Theriogenology* 62:450–457.
- Moore GPM, Jackson N, Isaacs K, Brown G. 1998. Pattern and morphogenesis in skin. *J Theor Biol* 191:87–94.
- Murphy J, Arkins S. 2004. The orientation of facial hair whorls may be linked to the direction of idiosyncratic motor behavior in the horse. In: *Agricultural Research Forum*. p 38.
- Randle HD. 1998. Facial hair whorl position and temperament in cattle. *Appl Anim Behav Sci* 56:139–147.
- Salman MD, Hutchison J, Ruch-Gallie R, Kogan L, New JC, Jr., Kass P, Scarlett J. 2000. Behavioral reasons for relinquishment of dogs and cats to 12 shelters. *J Appl Anim Welfare Sci* 3:93–106.
- Smith DW, Gong BT. 1974. Scalp-hair patterning: its origin and significance relative to early brain and upper facial development. *Teratology* 9:17–34.
- Wang YS, Badea T, Nathans J. 2006. Order from disorder: self-organization in mammalian hair patterning. In: *Proceedings of the National Academy of Sciences of the United States of America*. Vol. 103: p 19800–19805.
- Weber B, Hoppe C, Faber J, Axmacher N, Fliessbach K, Mormann F, Weis S, Ruhlmann J, Elger CE, Fernandez G. 2006. Association between scalp hair-whorl direction and hemispheric language dominance. *Neuroimage* 30:539–543.
- Ziering C, Krenitsky G. 2003. The Ziering whorl classification of scalp hair. *Dermatol Surg* 29:817–821.